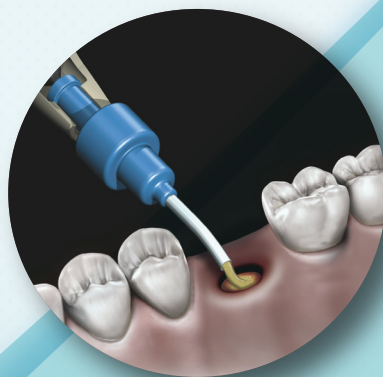
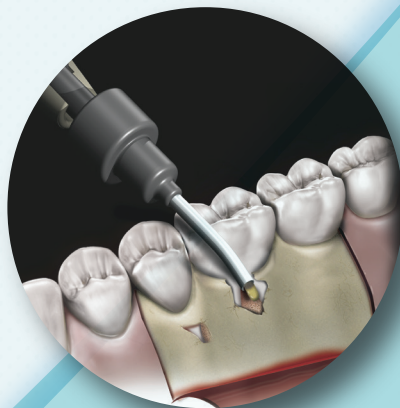
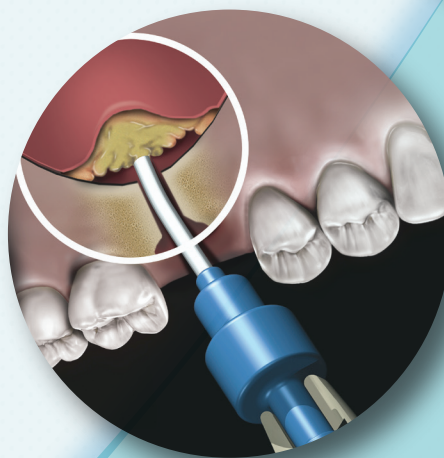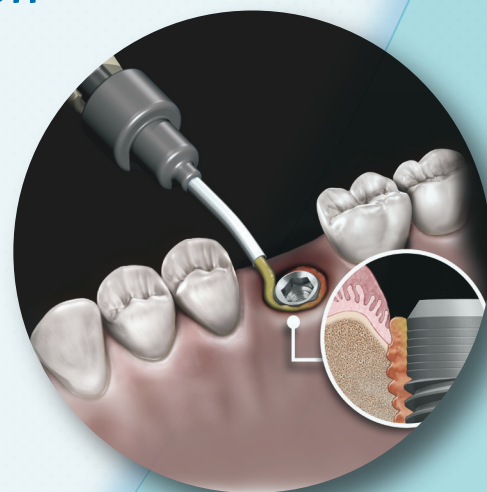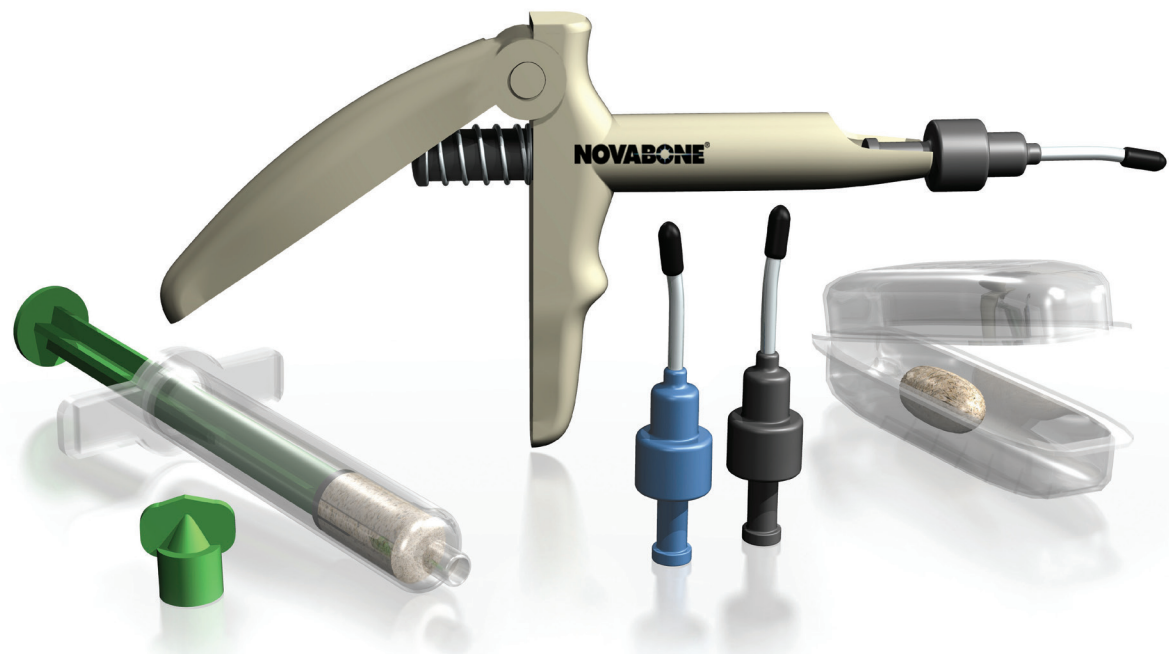NOVABONE[®] Dental Putty

The Synthetic Solution to Bone Regeneration



Posters & Publications

Uncommon Handling... ...Uncompromised Results!



NovaBone Putty is available in multiple dispensing systems. Variations are priced for affordability and efficiency. Products are available through a network of distributors world-wide, with a presence in over 40 countries.

CARTRIDGE SYSTEM

Cartridge Dispenser	each
0.5cc Cartridges (blue)	2/Pack
0.5cc Cartridges (blue)	4/Pack
0.5cc Cartridges (blue)	6/Pack
0.25cc Cartridges (grey)	4/Pack
0.30cc Cartridges (grey)	6/Pack

SYRINGE

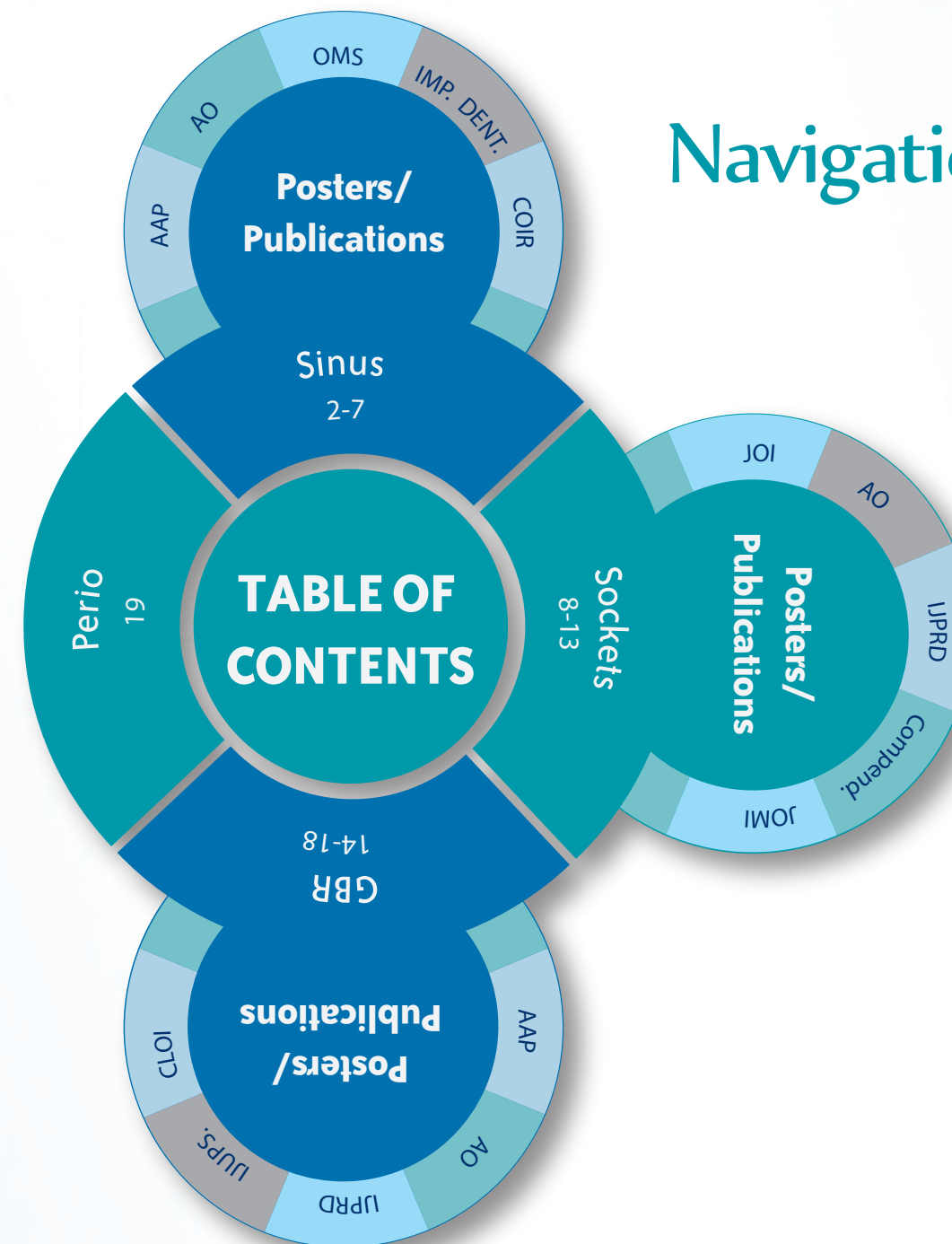
0.5cc Syringe	1/Pack
0.5cc Syringe	2/Pack
1.0cc Syringe	1/Pack
2.0cc Syringe	1/Pack

CLAM SHELL

0.5cc Shell	1/Pack
0.5cc Shell	2/Pack

Not all dispensing formats are available in all countries. Please check with your local distributor for sizes, part # and availability.

Navigation chart



Interpretation Key

Sinus Indications	- Pages 2-7
Socket / Ridge Regeneration	- Pages 8-13
GBR/Ridge Augmentation	- Pages 14-18
Periodontal Defects	- Page 19
Full list of publications	- Page 20

Select posters and publications are included in this catalog. For a complete list, please contact your local distributor.



Placement of Implants Simultaneously With Direct Sinus Lift in Ridges With Minimum Remaining Bone: Lack of Association and Primary Implant Stability

Thomas Nguyen⁺, Udatta Kher⁺⁺, Andreas Ioannou⁺,

⁺Advanced Education Program in Periodontology, University of Minnesota, MN, ⁺⁺Private Practice,

Ridges With Minimum Remaining Bone: Lack of Association and Primary Implant Stability

Lanka Mahesh^{*}, George Kotsakis⁺, James Hinrichs^{**}

Mumbai, India ^{*}Private Practice, New Delhi, India ^{**}Director, University of Minnesota, MN



Background

In case of minimum residual bone height, direct sinus augmentation is utilized prior to implant surgery to provide adequate ridge dimensions. Most clinicians consider 5mm of residual bone height to be the threshold for simultaneous sinus lift and implant placement.¹ In cases of ridges with minimum residual bone height, a staged approach can be a lengthy procedure that increases treatment time until final restoration. The present clinical investigation was conducted to assess the potential benefit of utilizing a putty bone graft with a viscous consistency² to ascertain primary implant stability during simultaneous implant placement in ridges with minimum residual bone height.

Aim

The aim of this retrospective study was to evaluate the clinical outcomes following placement of implants simultaneously with lateral window sinus augmentation with a calcium phosphosilicate (CPS) putty bone substitute (NovaBone Dental Putty, NovaBone Products Alachua, FL) in ridges with minimum residual bone height.

Materials & Methods

Seventeen healthy, adult patients with less than 5mm of vertical bone height in at least one posterior maxillary site, underwent sinus floor elevations according to a modification of the out fracture osteotomy technique.³ Neighboring sites that had greater than 5mm distance from the floor of the sinus were included in the analysis as a separate subgroup to evaluate the effect of residual bone height in primary implant stability.

Following elevation of the Schneiderian membrane, the CPS putty bone substitute was delivered pre-mixed using a cartridge delivery system and was directly injected into the prepared sinus cavity.⁴ A total number of 30 implants (Internal Tapered, BioHorizons, Birmingham, AL, USA) were inserted in the severely resorbed ridges (<5mm) and their neighboring sites (≥5mm) and primary implant stability for each subgroup was recorded.

Primary stability was recorded as the maximum insertion torque (MIT) achieved using a torque wrench for the placement of the implant in its final position.² Two distinct torque values were used as reference points (20N/cm², 35N/cm²) and the MIT for each implant was recorded as greater, equal or lesser than the corresponding reference.²

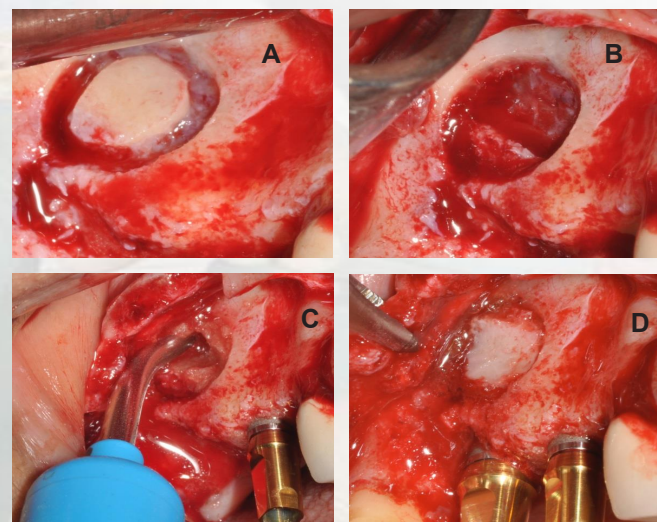


Figure 1:

- A. Intra-operative view of the prepared bony window on the lateral wall of the sinus with the aid of a piezotome.
- B. The out fractured bone wall was kept in saline throughout the procedure. Sinus curettes were utilized to perform careful elevation of the Schneiderian membrane across the floor of the sinus.
- C. The putty bone substitute was delivered into the sinus using a cartridge delivery system that simplified the grafting procedure. An implant in the second premolar position was placed in the native bone and thus excluded from the analysis.
- D. An implant in the 1st molar position was placed in the augmented sinus. The out fractured window was replaced in the lateral wall of the sinus.

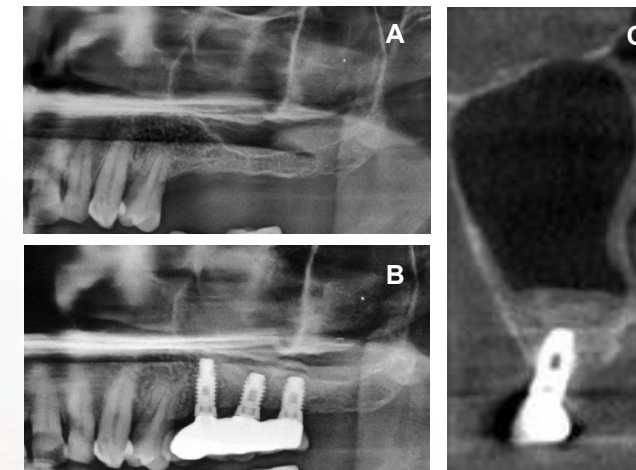


Figure 2:

- A. Pre-operative panoramic radiograph showing left pneumatized maxillary sinus.
- B. Post-operative panoramic radiograph showing left maxillary sinus 6 months after sinus elevation and implant placement surgery.
- C. Post-operative CBCT 6 months after sinus elevation and implant surgery showing new bone formation up to the tip of the implant.

Results

- No patients experienced any complications associated with the sinus surgery, or the implant placement. 0% sinus perforations.
- The preoperative ridge height ranged from 3.32mm to 8.14mm with 61.29% of the sites exhibiting less than 5mm of native bone height.
- In all cases (100%) at least 20N/cm² of MIT were achieved.
- Logistic regression analysis failed to show that the initial bone height of the residual ridges was associated with the MIT achieved during implant placement (P>0.05).
- At the second stage, appointment of the mean vertical bone height was 13.32mm (±1.82mm) as seen on post-operative radiographs. All implants successful osseointegrated (100% success). The difference between the initial vertical bone height and the bone height at the time of loading displayed a highly statistically significant difference (P<0.001)

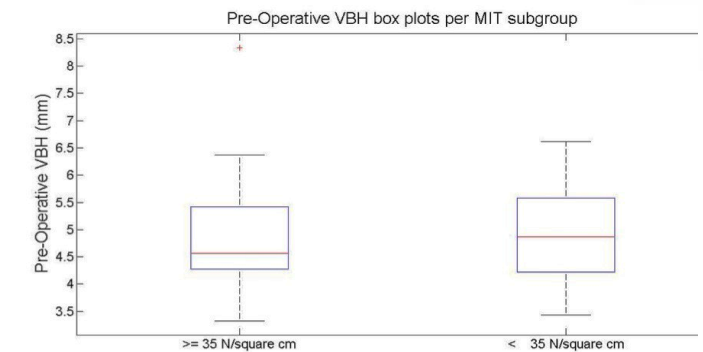


Figure 3:

Each box plot represents the median (red line) and the edges of the box are the 25th and 75th percentiles for the preoperative VBH measurements according to the maximum insertion torque (MIT) achieved during implant placement. The left subgroup represents VBH values for implants achieving at least 35N/cm² of MIT (n=19) and the right subgroup for those achieving less than 35N/cm² (n=12). The whiskers extend to the most extreme data points not considered outliers, and outliers are plotted individually. Note how similar the distribution of pre-operative values is in both subgroups. Logistic regression failed to reveal any association between the two values (P>0.05).

Conclusion

Within the limitations of this study, we conclude that:

- The placement of implants simultaneously with direct maxillary sinus lift utilizing the proposed technique for adequate primary stability may be a viable treatment option in severely resorbed posterior maxillary sites.
- The diminished preoperative vertical dimensions of the residual ridges did not seem to negatively influence the osseointegration of implants placed in this study.

References

1. Hürzeler MB, Kirsch A, Ackermann KL, Quiñones CR. Reconstruction of the severely resorbed maxilla with dental implants in the augmented maxillary sinus: a 5-year clinical investigation. Int J Oral Maxillofac Implants. 1996;11(4):466-75
2. Kotsakis GA, Salama M, Chrepa V, Hinrichs J, Gaillard P. A randomized, blinded, controlled clinical study of particulate Anorganic Bovine Bone Mineral and Calcium Phosphosilicate Putty bone substitutes for alveolar ridge preservation. Int J Oral Maxillofac Implants. 2014 Jan-Feb;29(1):141-51
3. Cho YS, Park HK, Park CJ. Bony window repositioning without using a barrier membrane in the lateral approach for maxillary sinus bone grafts: clinical and radiologic results at 6 months. Int J Oral Maxillofac Implants. 2012;27(1):211-7
4. Mazor Z, Ioannou A, Venkataraman N, Kotsakis G. A Minimally Invasive Sinus Augmentation Technique using a novel bone graft delivery system. Int J Implantol Clin Res 2013;4(2):78-82.



Use of a Viscoelastic Putty Alloplast for

Georgios A. Kotsakis⁺ James E.

⁺Advanced Education Program in Periodontology, University of Minnesota,

Minimally Invasive Indirect Sinus Elevation

Hinrichs⁺ Udatta Kher⁺⁺ Lanka Mahesh^{*}

MN, ⁺⁺Private Practice, Mumbai, India ^{*}Private Practice, New Delhi, India

Sept 29 – Oct 1, 2013

Philadelphia, PA

Background

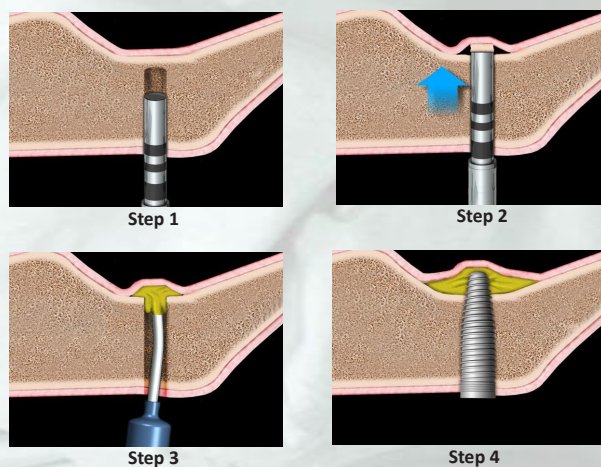
Use of percussive forces with osteotomes for indirect sinus elevation (ISE) is a successful modality despite incidence of schneiderian membrane (SM) perforation as high as 26% and reported benign paroxysmal positional vertigo (BPPV). Transalveolar sinus floor elevation (TSFE) employing hydraulic pressure has been advocated for ISE to minimize complications associated with osteotomes. This study used viscoelastic calcium phosphosilicate alloplastic putty (CPS) [NovaBone Dental Putty[®], NovaBone LLC, Alachua, FL] for TSFE. The viscoelastic biomaterial acts as a “protective cushion,” yet permits hydraulic pressure to lift the SM while minimizing risks of 1) BPPV or 2) mechanical perforations of SM associated with osteotomes. Purpose of this case series is to assess 6 months post-loading clinical, radiographic and patient-related outcomes following CPS use for TSFE with simultaneous implant placement.

Methods

Twenty patients (12 male, 8 female) exhibiting an edentulous maxillary posterior region with residual ridge height > 5mm were enrolled. Implant osteotomies were initiated to ~ 1mm below sinus floor, ~ 0.2cc of CPS putty injected to base of osteotomy, and sinus floor in-fractured via osteotome and mallet. Perforation of SM was assessed via palpable resistance with a sinus probe [Sinus Crestal Approach Kit, Zimmer Dental, Carlsbad, CA]. Additional 0.5cc increments of CPS were injected in osteotomy so implant insertion produced hydraulic pressure to elevate sinus floor and SM. Periapical radiographs obtained at right-angle projection were digitally calibrated using reference points on adjacent teeth to compensate for potential foreshortening measurements and Sinus Graft Remodeling Index (SGRI), respectively at 4-months post-surgery and 6-months post-loading.

Illustrations

Easy access into the sinus through crestal floor for sinus augmentation with Osteotome technique can be achieved in 4 simple steps. Step 1: Prepare the osteotomy to less than 1mm from the sinus floor. Step 2: An osteotome is then used to gently fracture the bone in the area. Step 3: The canula from the cartridge tip can be pressed against the surface of the bone and the putty is injected into the area resulting in membrane elevation with hydraulic pressure from Putty delivery. Step 4: An implant can then be placed in the augmented area.



Representative Case 1

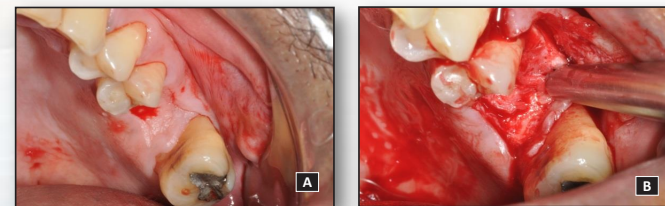


Fig A: Tracing of incisions

Fig B: Reflection of full thickness mucoperiosteal flap

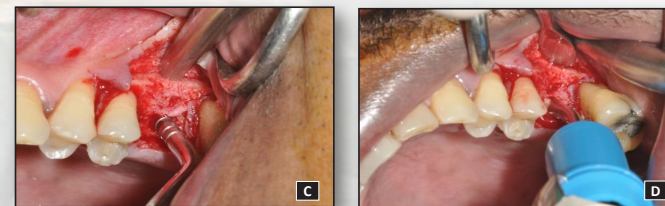


Fig C: Application of an osteotome following placement of a small quantity of putty that will function as a “cushion” during percussion of the sinus floor

Fig D: Adaptation of the cartridge in the osteotomy site and ejection of the CPS putty

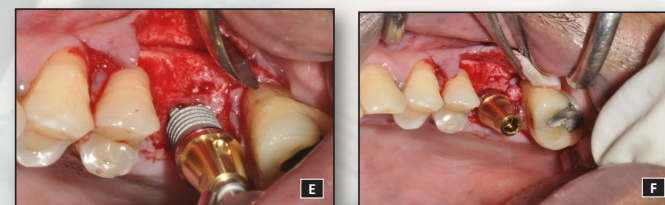


Fig E: Insertion of a Tapered Internal Implant in the osteotomy

Fig F: The implant achieved optimal primary stability

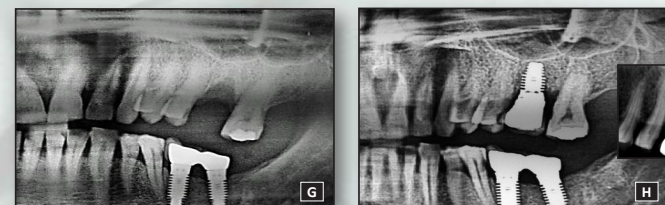


Fig G: Pre-operative radiographic view

Fig H: Post-loading radiographic view showing a radiopaque line delineating the new floor of the sinus

Representative Case 2

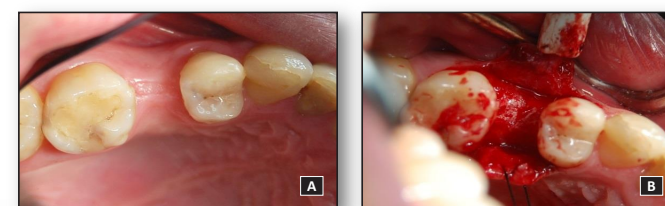


Fig A: Pre-operative clinical view. Treatment plan included TSFE with the use of a putty bone graft.

Fig B: Intra-operative view of the edentulous site. A routine envelope flap is adequate when employing this technique. No vertical releasing incisions are required.

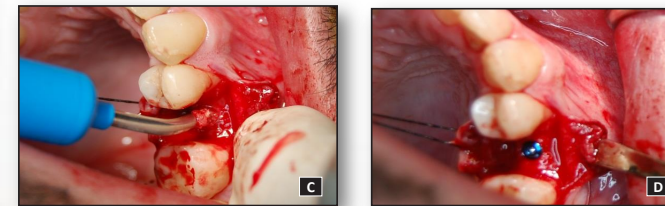


Fig C: Clinical photograph of the putty cartridge loaded on the delivery system. The narrow tip of the delivery system allows it to enter the narrow osteotomy (~2mm) and reach the floor of the sinus.

Fig D: Implant placed in its final positions with optimal primary stability

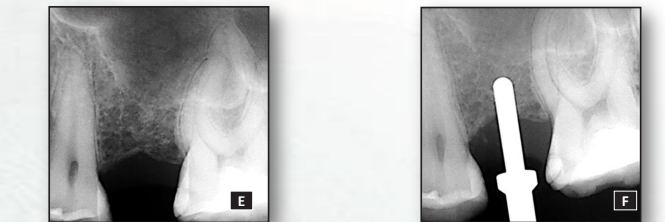


Fig E: Pre-operative radiographic examination revealed approximately 6mm of residual bone height.

Fig F: Radiographic view of the implant osteotomy stopped 1.5-2mm below the floor of the sinus.

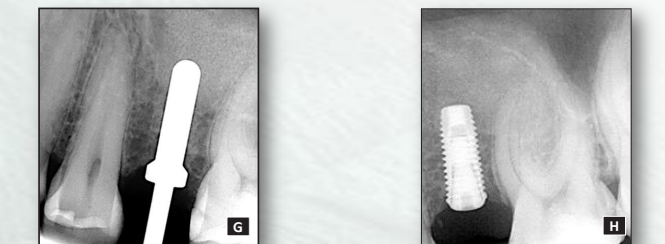


Fig G: Immediate post-sinus lift radiograph showing that the sinus elevation achieved was adequate.

Fig H: Radiographic image showing implant placement in the desired prosthetic position.

Results

Twenty-eight implants were placed in conjunction with TSFE utilizing CPS putty. All sites healed uneventfully. Median time to loading was 4 months. Mean residual ridge height was 7.34mm (SD ±1.41) (intra-observer r = 0.89). Incidence of intraoperative SM perforations and/or BPPV was zero. At implant insertion a mean 2.71mm (SD ±1.36) of linear radiopaque CPS graft was apical to the implant while original sinus floor lamina dura was still recognizable (SGRI-score 1). At mean 16 months follow-up (range 7-31 months) CPS was reduced to 1.71mm (SD ±1.26). A “new sinus floor outline” (SGRI-score 3) was noted in 81.25% of patients. Mean linear radiographic bone gain was 4.95mm (SD ±1.99). All implants were osseointegrated at 6-months post-loading for 100% survival rate. No biological or restorative complications noted. All patients indicated treatment outcome as “highly satisfied.”

Discussion

The presented technique utilizes a simplified minimally invasive TSFE technique¹ based on the application of hydraulic pressure by a viscous bone graft that acts as an incompressible fluid. The continuous flow of the viscous biomaterial via a cartridge system² results in the gradual and continuous elevation of the membrane.³ The use of the presented technique for sinus floor elevation may offer a conservative approach for localized augmentation of the sinus floor while minimizing postoperative complications.⁴ The consistency of the putty helps in minimizing membrane perforations and associated adverse events during percussion with osteotomes.

Conclusion

Use of viscoelastic CPS putty for TSFE provides a clinically safe and effective option for simultaneous placement of implants with minimal complications or post-operative morbidity.

References

- 1.Kfir E, Kfir V, Eliav E, Kaluski E. Minimally invasive antral membrane balloon elevation: report of 36 procedures. J Periodontol 2007;78(10):2032-5
- 1.Mazor Z, Ioannou A, Venkataraman N, Kotsakis G. A Minimally Invasive Sinus Augmentation Technique using a novel bone graft delivery system. Int J Oral Implantol Clin Res 2013;4(2)
- 2.Kotsakis G., Chrepa V., Marcou N., Prasad H., Hinrichs J. Flapless alveolar ridge preservation utilizing the “socket-plug” technique: clinical technique and review of the literature. In *Press*, November 2012. Journal of Oral Implantology.
- 3.Mazor Z, Kfir E, Lorean A, Mijiritsky E, Horowitz RA. Flapless approach to maxillary sinus augmentation using minimally invasive antral membrane balloon elevation. Implant Dent 2011;20(6):434-8

Implants placed simultaneously with lateral window sinus augmentation using a putty alloplastic bone substitute for increased primary implant stability: a retrospective study.

Kher U, Mazor Z, Stanitsas P, Kotsakis GA.

Introduction: The aim of this retrospective study was to evaluate the primary stability of implants placed in significantly pneumatized maxillary sinuses with minimum residual bone height.

Methods: Seventeen patients who had been treated with simultaneous implant placement in sites with <5 mm of vertical bone height using a modified direct sinus lift technique were included. Implants placed in adjacent sites with at least 5 mm of bone height were included as quasi-controls.

Results: A total of 30 implants were inserted with a maximum insertion torque number >20 N/cm. Logistic regression analysis failed to show any association between residual bone height and primary implant stability. Implant survival was 96.67% (29/30) during a mean follow-up of 15.74 months postloading.

Conclusions: The diminished preoperative vertical dimensions of the residual ridges did not seem to negatively influence the osseointegration of implants placed in this study. The prerequisite for simultaneous sinus augmentation and implant placement is an adequate primary stability of the implant and not a fixed minimum bone height level.



Implant Dentistry 2014 Aug 23(4):496-501

Sinus elevation with an alloplastic material and simultaneous implant placement: a I-stage procedure in severely atrophic maxillae.

Jodia K, Sadhwani BS, Parmar BS, Anchlia S, Sadhwani SB.

Aim & Objective: The aim of the study is to evaluate clinically and radiographically the long term success of one-stage direct (lateral) sinus lift procedure using alloplastic bone graft material and bio-absorbable membrane in conjunction with two stage implant placement in atrophic partially edentulous posterior maxilla.

Methods: One stage direct maxillary sinus lift in conjunction with two stage implant placement was carried out in 12 patients at 13 sites. All the patients were partially edentulous with posterior maxillary alveolar ridge height of >5 mm. Bioactive glass putty, bio-absorbable collagen membrane and 3.75 × 11.5 mm implants were used. Loading of implants was done 6 months after placement of implants. Patients were evaluated clinically and radio-graphically 6, 18, 30 months after placement of implants to assess increase in residual ridge height, peri-implant condition (marginal bone loss, plaque and gingival index) and implant stability.

Results: Maxillary first molar was the most common site (69.23 %) for sinus lift and implant placement. Caries was the most common cause (76.92 %) for loss of tooth. Increase in residual ridge height ranged from (71.43 to 133.33 %) as measured by Denta-Scan. Implant survival rate was 100 %. Marginal bone loss ranged from 0.68 to 1.22 mm. Implant stability was measured by periotest (-2.7 to -3.6). Only one patient had perforation of sinus membrane, but it was sealed satisfactorily by bio-absorbable membrane

Conclusions: One stage lateral sinus lift procedure with alloplastic bone graft material in combination with 2 stage implant placement has a predictable outcome in patients with severe resorption of posterior maxilla

J Maxillofac Oral Surg. 2014 Sep;13(3):271-80

A simplified approach to the minimally invasive antral membrane elevation technique utilizing a viscoelastic medium for hydraulic sinus floor elevation.

Kotsakis GA, Mazor Z.

Purpose: Maxillary sinus augmentation surgery is frequently employed to provide adequate vertical bony dimensions in posterior maxillary sites. When significant gain in bone height is sought for, an invasive lateral-window approach is routinely used to achieve sinus floor elevation. The minimally invasive antral membrane elevation technique was initially conceived as a surgical improvisation that has been shown to lead to up to, or exceeding, 10 mm of bone height, while enhancing the safety profile of the transalveolar sinus augmentation technique. This approach is based on the use of hydraulic pressure that is applied to the Schneiderian membrane via a saline-inflatable balloon. Even though this technique has been shown to be a safe and efficacious treatment modality, the need for specialized equipment, training, and corresponding costs may hinder its widespread application. The purpose of this clinical paper is to introduce a simplified approach to the minimally invasive antral membrane elevation technique.

Methods: The simplified minimally invasive antral membrane elevation technique is based on the application of hydraulic pressure by a viscous bone graft that acts as an incompressible fluid. The specific clinical steps of this technique will be demonstrated to illustrate how grafting of the maxillary sinus is achieved simultaneously with the atraumatic elevation of the Schneiderian membrane, thus resulting in even less operative time.

Conclusions: This simplified technique may make the minimally invasive antral membrane elevation technique more accessible to implant surgeons as it eliminates the need for purchase of specialized equipment and aids in further decrease of intra-operative time accomplished with the original technique.

Oral Maxillofacial Surg. 2015 19:97-101

Clinical and histologic comparison of two different composite grafts for sinus augmentation: a pilot clinical trial.

Galindo-Moreno P, Avila G, Fernández-Barbero JE, Mesa F, O'Valle-Ravassa F, Wang HL.



Background & Objectives: Many different techniques as well as bone graft regimens have been suggested for performing this procedure. It was the goal of this study to compare, clinically and histologically, two different composite grafting regimens used for sinus augmentation.

Materials & Methods: Five patients, needing a bilateral sinus augmentation to allow implant placement, were recruited for this study. Right sinuses were grafted with cortical bone (collected from overlying the sinus membrane) and bovine hydroxyapatite (HA), while the left side sinuses were grafted with overlying autologous bone plus a bioglass (BG) material. Bone core biopsies were taken at 6 months after sinus graft or at the time of implant insertion. A waiting period of 6 additional months was granted to allow healing, before prosthetic restoration and functional loading. The level of peri-implant bone was evaluated 12 months after loading. A comparative histomorphometric analysis was conducted and a statistical analysis was performed.

Results: All implants in both groups were functional after a 12-month loading period. No bone loss was observed radiographically or clinically in both groups. Histologic analysis revealed that both composite grafts had a high biocompatibility. In the bovine HA-containing group, minimal xenogenic graft absorption was noted. In contrast, BG group samples presented a high absorption rate with some remaining particles imbedded in new normal bone.

Conclusions: Sinus augmentation using a combination of autogenous bone plus either bovine HA or BG is a predictable technique.

Clin Oral Implants Res. 2008 Aug;19(8):755-9.

Histological and Clinical Evaluations of NovaBone

Sebastiano Andreana⁺ Ahmad Kutkut⁺⁺,

⁺University at Buffalo, School of Dental Medicine, Department of Restorative Dentistry, Buffalo, NY

Background

Alveolar bone loss following tooth loss is an ongoing process due to the lack of functional stimulation. The rate and degree varies among individuals, but is greatest (40% – 60%) during the first few months or years after tooth loss (1). Prosthetic reconstruction and replacement of teeth (and associated structures) becomes more difficult and often unsatisfactory when anatomic deformities in the jaw bone ridges occur. Available evidence suggests that alveolar bone ridge resorption may be attenuated or prevented, at least initially, by reconstructive surgical techniques employed at the time of tooth removal. Several materials have been promoted for ridge preservation and include socket filling materials such as non-resorbable hydroxylapatites (particulate or solid block) and polymers (such as HTR Synthetic Bone), resorbable materials such as autogenous bone, particulate freeze-dried bone allograft (demineralized or non-demineralized), natural hydroxylapatite (bovine and equine derived), synthetic "resorbable" hydroxylapatites, and tricalcium phosphate; and both non-resorbable (e-PTFE) and resorbable (collagen or polylactic acid-type) guided tissue regeneration barriers (2). Furthermore, the bone graft materials have been marketed primarily as in form of particles as well putty.

The purpose of this clinical study was to assess the clinical and histological outcomes of two marketed putty graft materials used for socket preservation following dental extractions, one being an allograft, one an alloplast. This is a clinical and histological study with limited data submitted at this time.

Materials and Methods

For this study, an Alloplast material in putty form, NovaBone (NovaBone Products) was used in comparison with an allograft in putty form, Dynablast (Keystone, Inc). Upon institution's IRB approval, generally-healthy males and females volunteers adult between the age of 18 and 75, were scheduled for extraction of single-rooted-teeth and socket preservation; upon enrollment, subjects were randomly assigned to either NovaBone Dental Putty or Dynablast at time of tooth-extraction; reason for extraction was non restorability of the involved teeth (1A-2A).

Surgical Procedure

The extraction procedures followed the method previously described by Kutkut et al (3). Briefly, following gaining anesthetic effect with local infiltration of anesthetic agents, the sulcus of the teeth was incised (1B-2B). Periostomes were used to gently luxate the tooth to gain mobility, then extraction forceps used to remove the tooth (1C-2C). The socket were then degranulated with Bone curettes, and then grafted. The graft materials were inserted in the sockets up to reach the alveolar bone crest (1E, 2E). The grafted sockets were covered with a collagen membrane (Conform, ACE) positioned under the unsupported free gingival margin, without elevation of any flap (1F, 2F). The margins of the socket were sutured with Cytoplast 3.0 (Cytoplast). During the suturing procedure, the collagen membrane was protected with a small periosteal elevator, with the intent of not engaging the barrier with the suture (1G, 2G). Clinical measurements at baseline and 5 months included: presence of attached gingiva (AG), ridge width (RW) at the crest, ridge width at 10mm apically to the crest (1D-, 2D). Membrane exposure was also measured following suturing and at 1 and 2-weeks post-op to monitor the wound closure.

Bone biopsies were harvested at 5-7 months (1H-1I, 2H-2I) when implants were placed (1J, 2J) with primary stability at 35 Ncm. Bone cores were immersed in 10% buffered formalin and processed for undecalcified histological analysis. At this time, preliminary clinical data from 8 subjects, 4 for each group, are presented. However, histological data for 7 subjects (NovaBone n=3; Dynablast n=4) are presented.

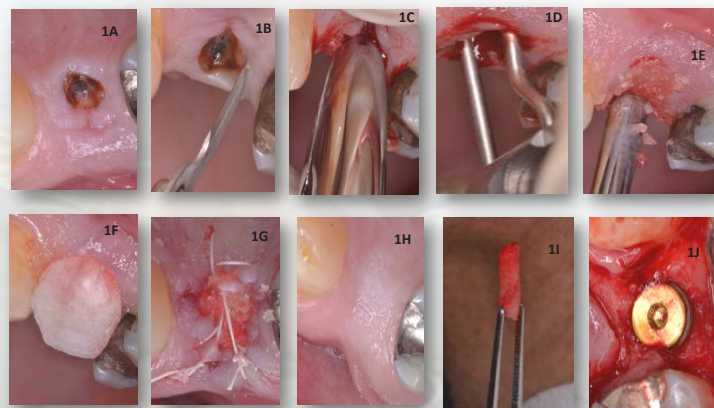


Fig 1A-1J Dynablast Group

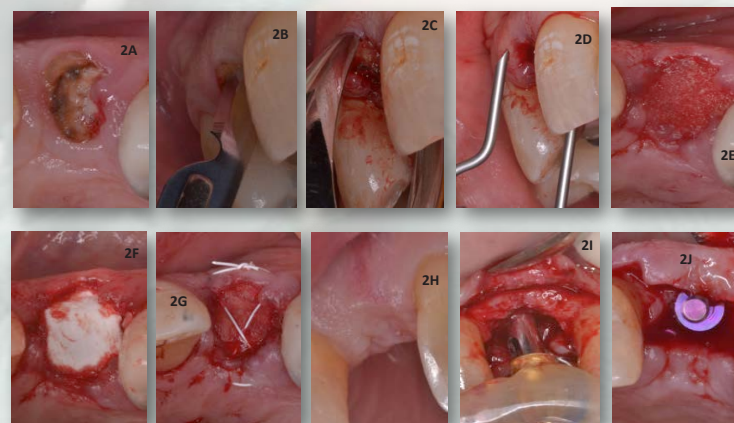


Fig 2A-2J NovaBone Group

Dental Putty vs. Dynablast in Extraction Sockets

Bandar A. Almaghrabi⁺, Dana Qeblawi⁺, Carla Beneduce⁺

⁺⁺ University of Kentucky, College of Dentistry, Department of Restorative Dentistry, Lexington, KY.

Results

Mean values for AG were 3.75mm (±1.89) at baseline and 5.25mm (±1.25) at 5 months for NovaBone (n=4); 5.75mm (±2.75) at baseline and 6.0mm (±1.41) at 5 months for Dynablast. Differences between the 2 groups were not statistically significant. Mean values for RW at the crest were 8.25mm (±2.36) at baseline and 6.75mm (±2.5) at 5 months for NovaBone; for Dynablast, values were 7.75mm (±0.95) at baseline and 7.63mm (±2.05) at 5 months. Measurements of the RW 10mm apical to the crest were 13.87mm (±3.37) at baseline and 13.5mm (±2.38) at 5 months for NovaBone; for Dynablast, 12.5mm (±1.73) and 12.5mm (±2.38). There were no statistically significant differences between the 2 groups. For NovaBone, collagen exposures mean values were approximately 38.07mm² (±7.43) after extraction to 17.2mm² (±3.68) at week 1 and 5.29mm² (±3.58) at week 2; for Dynablast, 27.66mm² (±14.62) to 11.96mm² (±11.14) at 1 week and 7.85mm² (±5.28) at 2 weeks.

	NovaBone		Dynablast (mm)	
	Baseline	5 Months	Baseline	5 Months
Attached Gingiva (AG) (mm)	3.75 ± 1.89	5.25 ± 1.25	5.75 ± 2.75	6.0 ± 1.41
Ridge Width (RW)- Crest (mm)	8.25 ± 2.36	6.75 ± 2.5	7.75 ± 0.95	7.63 ± 2.05
RW- 10mm apical to crest (mm)	13.87 ± 3.37	13.5 ± 2.38	12.5 ± 1.73	12.5 ± 2.38

Table 1: Clinical Measurement Data at baseline and 5 months post-operative

Histomorphometry

A 2.7mm inner diameter trephine was used to obtain the core from the center of the grafted area upon re-entry at 5 months to evaluate the quality and quantity of bone. The cores were preserved in 10% formalin and sent to the Hard Tissue Laboratory at University of Minnesota for histological & histomorphometric analysis. Upon receipt, specimens were dehydrated with a graded series of alcohols for 9 days. Following dehydration, the specimens were infiltrated with a light-curing embedding resin (Technovit 7200 VLC, Kulzer, Wehrheim, Germany). Following 20 days of infiltration with constant shaking at normal atmospheric pressure, the specimens were embedded and polymerized by 450 nm light. Specimens were prepared in an apico-coronal direction and were cut into a thickness of 150 µm on a cutting/grinding system (EXAKT Technologies, Oklahoma City, OK). The cores were polished to a thickness of 45-65 µm using a micro-grinding system. The slides were stained with Stevenel's blue and Van Gieson's picro fuchsin and cover-slipped for histologic analysis using bright-field and polarized microscopy

	% New Bone	% Marrow Space	% Residual Graft
NovaBone	33.01	58.49	8.5
Dynablast	30.22	53.05	16.73

Table 2: Five Month Post-Op Comparative Histomorphometric Results




Fig 3A: NovaBone 40x magnification at 5 mos.




Fig 3B: Dynablast 40x magnification at 5 mos.

Representative histological sections at 5 months for both NovaBone & Dynablast show good bone incorporation throughout the grafted area with some residual graft material. A higher percentage of residual graft substitute was noticed with Dynablast samples. The percentage of new bone was higher for NovaBone samples and was statistically significant.

Discussion

Several materials can be used as graft immediately following tooth extraction, to preserve alveolar ridge dimensions, with the aim of future simple implant placement. Putty materials have been used, particularly allografts and alloplasts, such as bioactive phosphosilicate putty. The results of this study indicates that both materials can be used, and that clinician or patients choice can be satisfied with either materials. In the present study, approx. 5-7 months following extraction, osteotomies prepared in either graft material sockets, and implants placed, resulted in implant primary stability. The data confirms that bioactive calcium phosphosilicate can be used as bone graft for socket preservation (4)

Conclusion

Although these are preliminary data and no final conclusions can be made, a trend is observed indicating that synthetic putty bone graft performs as well as Human Demineralized putty bone graft material in socket preservation procedures. However, the synthetic putty bone graft seems to favor soft tissue healing. Histologically, the percentage of residual graft material for the human demineralized putty material is higher than the synthetic material tested in this study.

References

1. Van der Weijden F, Dell'Acqua F, Slot DE. Alveolar bone dimensional changes of post-extraction sockets in humans: a systematic review. J Clin Periodontol. 2009 Dec;36(12):1048-58.
2. Ten Heggeler JM, Slot DE, Van der Weijden GA. Effect of socket preservation therapies following tooth extraction in non-molar regions in humans: a systematic review. Clin Oral Implants Res. 2010 Nov 22
3. Kutkut A, Andreana S, Kim, HI, Monaco E Jr. Extraction socket preservation graft before implant placement with calcium sulfate hemihydrate and platelet-rich plasma: a clinical and histomorphometric study in humans. J Periodontol. 2012 Apr;83(4):401-9.
4. Gonshor A, Saroff SA, Anderegg CR, Joachim FPC, Charon JA, Prasad H, Katta S. Histologic and Clinical evaluation of a bioactive calcium phosphosilicate bone graft material in postextraction alveolar sockets. Int J Oral Implantol Clin Res. 2011 May-August; 2(2) 79-84.

Background

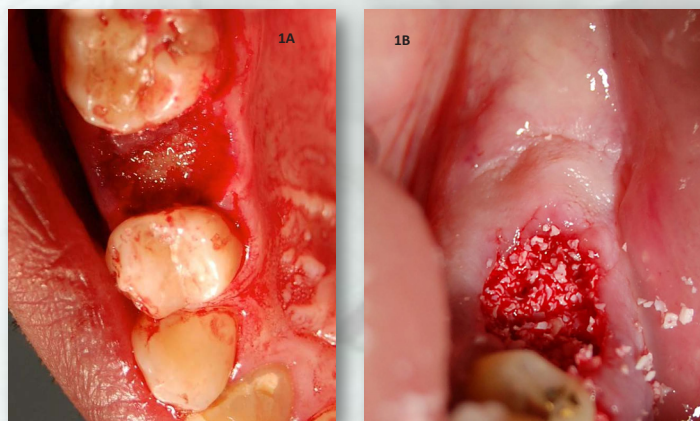
Ridge preservation procedures aim in the timely regeneration of bone in the extraction socket and the preservation of the alveolar ridge dimensions during the healing period to provide a favorable site for implant placement.^{1, 2} Different biomaterials exhibit individualized absorption rates and lead to different percentages of vital bone formation in the healed sockets.^{3,4} The aim of this study was to histologically evaluate and compare bone regeneration in post-extraction sockets utilizing either a putty calcium phosphosilicate alloplastic bone substitute (CPS Putty) (NovaBone Dental Putty, NovaBone Products, Alachua, FL) or a particulate bovine xenograft (BO) (Bio-Oss, Osteohealth, Shiry, NY) for ridge preservation.

Methods

Twenty-two patients with a mean age of 51 years old scheduled to undergo tooth extractions and ridge preservation were included in this study. Willing participants signed the consent form and were enrolled in the study. The study was conducted in accordance with the Helsinki Declaration of 1975, as revised in 2000. Patients were recalled after 4 or 6 months according to a randomization list to evaluate healing and to obtain a core for histological analysis during implant placement.

Exclusion criteria:

- Medical history that contraindicates surgical treatment
- Medications that alter soft or bone tissue healing (eg bisphosphonates, chronic steroid intake, etc)
- Pregnancy for females
- Acute periodontal or odontogenic disease
- Destruction of more than 50% of the buccal plate at the time of extraction



Figs 1: Placement of CPS Putty (Fig1A) or Bovine xenograft particles (Fig1B) in post-extraction sockets

Surgical Procedure

Ridge preservation was performed by utilizing the socket-plug technique as previously described by Kotsakis et al. (2012)⁵. Briefly, at the surgical appointment, care was taken to extract the teeth atraumatically in an attempt to preserve the remaining bone structure. Following extraction, the sockets were meticulously debrided and any inflammatory tissue was removed. Either a calcium phosphosilicate alloplastic putty (CPS Putty) was placed into the sockets using a cartridge delivery system without any prior mixing or further manipulation, or particles of an anorganic bovine xenograft were mixed with sterile saline and packed into the socket. A collagen plug was utilized to occlude the sockets and a horizontal mattress suture was used to stabilize it. No pre or post-operative antibiotics were administered, and all patients were placed on 0.12% chlorhexidine oral rinse post-operatively. Analgesics were prescribed on a need basis (Ibuprofen, 400mg). Postoperative evaluations were performed at 7 and 14 days and at 4 weeks to assess wound healing and record any adverse events.

Histomorphometry

Following either 4 (subgroup 1) or 6-months (subgroup 2) of healing, surgical reentry was performed in the healed ridges for implant placement. Prior to the initiation of the osteotomies, a trephine bur with a 2.7 mm – 3.0 mm internal diameter was used to obtain a bone core from each site. The cores were preserved in 10% formalin and sent to the Hard Tissue Laboratory at University of Minnesota for histological & histomorphometric analysis. Upon receipt, specimens were dehydrated with a graded series of alcohols for 9 days. Following dehydration, the specimens were infiltrated with a light-curing embedding resin (Technovit 7200 VLC, Kulzer, Wehrheim, Germany). Following 20 days of infiltration with constant shaking at normal atmospheric pressure, the specimens were embedded and polymerized by 450 nm light. Specimens were prepared in an apico-coronal direction and were cut into a thickness of 150 µm on a cutting/grinding system (EXAKT Technologies, Oklahoma City, OK). The cores were polished to a thickness of 45-65 µm using a micro-grinding system. The slides were stained with Stevenel's blue and Van Gieson's picro fuchsin and cover-slipped for histologic analysis using bright-field and polarized microscopy

Results

Post-operative healing was uneventful in all sockets from both the test groups. Histomorphometry revealed that the residual graft values were significantly higher in the xenograft group compared to the alloplast group at the 6 month observation period. For cores harvested at 4 months post-extraction the amount of residual bone graft in the xenograft group was higher as well, but the difference did not reach statistical significance. Table 1 displays vital bone in defects filled with CPS Putty that ranges from 36% - 57% (average 47.15% ± 8.5%). Residual bone graft (RBG) was found to range from 30% at 4months to a minimum of 3% at 6 months and an average of 17.4% ± 9.4%. The vital bone values in the BO group (Table 1) ranged between 17% - 27% (average 22.2% ± 3.5%). The difference in vital bone volume between the two groups was found to be statistically significant in favor of the CPS putty group P<0.05. Specimens in the BO group showed a range of RBG of a maximum of 38% at 4 months to a minimum of 18% at 6 months with an average of 25.7% ± 5.9%.

Poster Presented at the Academy of Osseointegration

NovaBone				Bio-Oss			
Tooth #	Months	% Bone	% RBG	Tooth #	Months	% Bone	% RBG
14	6	55	3	45	4	17	38
35	4	38	24	23	6	22	26
11	4	55	18	13	6	19	24
21	5	41	26	11	6	24	20
24	6	41	13	35	5	26	26
25	5	55	8	33	6	26	22
21	4	40	28	44	4	18	32
11	4	36	30	15	6	21	28
44	5	54	16	24	6	27	18
24	6	57	8	25	6	22	23

Table 1: % Vital Bone & Residual Graft (RBG) values of both CPS & BO at varying time periods

% Residual Graft	CPS Putty	BO
4 months	23.67 ± 5.57*	35.00 ± 4.24
6 months	8.00 ± 4.08**	23.14 ± 3.44
All Samples	17.40 ± 9.39*	25.60 ± 5.89

*Indicates statistically significant (P <0.05) reduction in RBG values in favor of CPS Putty group
** Indicates a highly statistically significant (P<0.001) reduction in RBG values in favor of CPS Putty group

Table2: Comparative evaluation of the RBG % between two study groups at two time intervals

Histology

Representative histological slides from both CPS Putty & BO groups at 6 months re-entry are presented below. Figures 2 A, B & C show bone biopsy images for CPS Putty at various magnifications (20x, 40x & 100x). Red stained tissue is mineralized newly regenerated bone. Some residual bone graft particulate can be seen in all sections. Figures 3 A, B & C show bone biopsy images for BO group. Large remnants of residual graft particulate can be clearly visualized.

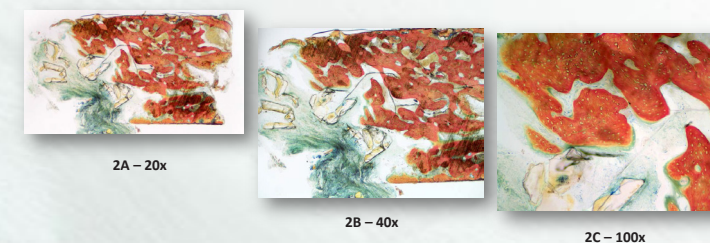


Fig 2: A-C: Increasing magnifications of CPS core biopsy at 6 months. Newly mineralized bone (red areas) can be clearly seen along with some residual graft particulate)




Fig 3: A-C: Increasing magnifications of BO core biopsy at 6 months. Note higher number of residual graft particulate

Discussion

Historically, the function of biomaterials has been to replace damaged and missing tissues. In contemporary implant dentistry, the aim of ridge preservation is to provide a healed site with adequate dimensions and favorable bone quality for the successful placement of an implant in the most timely manner. The quality and quantity of the regenerated bone should allow for the placement of an implant surrounded by bone tissue able to withstand functional loading. Results of histological analysis in our study revealed bone formation in sockets implanted with both biomaterials, with sockets grafted with CPS putty displaying consistently more bone regeneration than those in the bovine xenograft group. A similar percentage of residual bone graft was found at 4 months post-extraction in sockets of both groups with the those in the CPS putty group exhibiting a slightly smaller percentage in comparison to those in the bovine xenograft group. At the 6 month interval, sockets in the CPS putty group exhibited a statistically significant smaller amount of residual bone graft demonstrating the continued bone turnover in the CPS putty group, whereas in the xenograft group, the amount of reduction in the percentage of residual bone particles was not statistically significant between 4 and 6 months, implying that this graft requires a protracted period of healing.

Conclusion

The higher percentage of residual bone graft in the xenograft group in comparison to the CPS putty indicates an increased graft turnover rate in the latter group. Results from this study demonstrate that CPS putty may be the material of choice in comparison to anorganic bovine bone xenograft in ridge preservation procedures when timely implant placement is the desired outcome. Further randomized clinical trials are required to investigate whether the increased amount of new bone formation in the CPS putty group has a clinical impact on implant survival.

References

1. Barteek BK. Extraction site reconstruction for alveolar ridge preservation. Part 1: rationale and materials selection. *J Oral Implantol.* 2001;27(4):187-93.
2. Gross J. Ridge preservation using HTR synthetic bone following tooth extraction. *Gen Dent.* 1995 Jul-Aug;43(4):364-7
3. Carmagnola D, Adriaens P, Berglundh T. Healing of human extraction sockets filled with Bio Oss. *Clin Oral Implants Res* 2003;14:137-143.
4. Mahesh L, Salama MA, Kurtzman GM, Joachim FP. Socket grafting with calcium phosphosilicate alloplast putty: A histomorphometric evaluation. *Compendium Contin Educ Dent.* Sept 2012; 33(8):109-115
5. Kotsakis G, Chrepa V, Marcou N, Prasad H., Hinrichs J. Flapless alveolar ridge preservation utilizing the "socket-plug" technique: clinical technique and review of the literature. *J Oral Implantol.* 2012 Nov 12.

Annual Meeting, Mar 7 – Mar 9 2013, Tampa, FL

A Randomized, Blinded, Controlled Clinical Study of Particulate Anorganic Bovine Bone Mineral and CPS Putty Bone Substitutes for Socket Preservation.

Kotsakis, GA, Salama M, Chrepa V, Hinrichs JE, Gaillard P.

Introduction: The purpose of this study was to compare the clinical efficacy of an anorganic bovine bone graft particulate to that of a calcium phosphosilicate putty alloplast for socket preservation.

Methods: Thirty teeth were extracted from 24 patients. The sockets were debrided and received anorganic bovine bone mineral (BOV, n=12), calcium phosphosilicate putty (PUT, n=12), or no graft (CTRL, n=6). The sockets were assessed clinically and radiographically 5 months later. Eight sockets in the BOV group and nine in the PUT group received implants 5 to 6 months post-grafting. The maximum implant insertion torque (MIT) was measured as an index of primary implant stability. The data were analyzed with the Mann-Whitney test.

Results: Both test groups had statistically significantly less reduction in mean ridge width (BOV: 1.39 ± 0.57 mm; PUT: 1.26 ± 0.41 mm) in comparison to the control group (2.53 ± 0.59 mm). No statistically significant difference was identified between the test groups. MIT for PUT was ≤ 35 N/cm² (MIT grade 4) for seven of the nine implants. MIT values in the BOV group ranged from grade 1 (10 to 19 N/cm²) to grade 4, which was statistically significantly lower than for the PUT group. The overall implant success rate was 94.1% (16 of 17 implants were successful). No implants were lost in the PUT group; one implant failed in the BOV group.

Conclusions: Both tested bone substitutes can be recommended for preservation of alveolar ridge width following extraction. PUT might be more suitable for achieving primary stability for implants placed at 5 to 6 months postextraction..



Int J Oral Maxillofac Implants. 2014 Jan-Feb;29(1):141-51.

Clinical Evaluation of 262 Osseointegrated Implants Placed in Sites grafted with Calcium Phosphosilicate Putty: A Retrospective Study.

Babbush CA, Kanawati A.

Objective: Along with the widespread use of dental implants, regenerative procedures have become an indispensable tool for the management of residual ridges as well as the surrounding bone, by the implant surgeon. Putty bone grafts enjoy significantly superior handling characteristics in comparison to particulates. These include ease of placement, enhanced particle containment and a viscous consistency that has allowed for unique delivery systems to be developed. The aim of this study was to report the clinical efficacy of calcium phosphosilicate (CPS) putty in a wide variety of indications related to implant reconstruction and to report the survival rate of implants placed in these grafted sites.

Methods: CPS putty was utilized as the graft material of choice. Indications were categorized into following groups: Extraction graft, Extraction with immediate implant placement, All-On-four concept, Peri-implantitis treatment, Bone augmentation prior to implant placement, Implant replacement graft, Grafting around implant placed in resorbed ridges.

Results: Sixty-five patients (36 men, 29 women), with a mean age of 63 ± 12 years were included in the analysis. In total 262 implants were placed. Four implants were diagnosed with peri-implantitis and were treated as described in category 4, for a total of 266 grafted sites. Two implants from the extraction graft category and three implants from the all-on-four group were lost and replaced with successfully osseointegrated implants during a mean study follow-up period of 12.24 ± 2.32 months. The implant success rate at one year was 98.1% (257/262).

Conclusions: Based on results of this large scale, retrospective study we conclude that: 1) the use of putty bone grafts can simplify bone-grafting procedures and reduce intra-operative time in various grafting indications, 2) this study verified the efficacy of a CPS putty bone graft biomaterial in a large array of implant-related surgical indications, and 3) implants placed in sites grafted with CPS putty yield very high survival rates.

J Oral Implantol. 2015 Feb;41(1):63-9.

Histomorphometric evaluation of a calcium-phosphosilicate putty bone substitute in extraction sockets.

Kotsakis GA, Joachim FP, Saroff SA, Mahesh L, Prasad H, Rohrer MD.

Objective: The objective of this study was to evaluate bone regeneration in 24 sockets grafted with a calcium phosphosilicate putty alloplastic bone substitute.

Methods: A core was obtained from 17 sockets prior to implant placement for histomorphometry at 5 to 6 months postextraction. Radiographic analysis during the same postextraction healing period showed radiopaque tissue in all sockets.

Results: Histomorphometric analysis revealed a mean vital bone content of 31.76% ($\pm 14.20\%$) and residual graft content of 11.47% ($\pm 8.99\%$) after a mean healing period of 5.7 months.

Conclusion: The high percentage of vital bone in the healed sites in combination with its timely absorption rate suggest that calcium phosphosilicate putty can be a reliable choice for osseous regeneration in extraction sockets.



Int J Periodontics Restorative Dent. 2014 Mar-Apr;34(2):233-9.

Socket Grafting with Calcium Phosphosilicate Alloplast Putty: A Histomorphometric Evaluation

Mahesh L, Salama MA, Kurtzman GM, Joachim FP.

Background: Socket grafting with a bone graft substitute immediately after extraction is essential to preserve the ridge architecture for implant placement. Several bone graft substitutes have been tested for their ability to effectively regenerate osseous tissue in the sockets. Evidence suggests that socket bone typically regenerates during a period of 6 to 8 months or longer, depending on several factors including the original ridge dimensions, type of graft, and the overall systemic health of the individual. The purpose of this study is to histologically evaluate the bone regeneration potential of a novel synthetic calcium phosphosilicate putty (CPS) graft substitute.

Methods: After extraction of the involved teeth, CPS putty graft was placed, and the sockets were covered with a collagen plug. Cores were taken from 20 patients for histological evaluation prior to implant placement. Ten cores were processed decalcified with hematoxylin and eosin (H&E) stain and the remaining 10 were processed undecalcified. Histomorphometric data obtained from both sets is presented.

Results: Histomorphometric analysis revealed an average vital bone content of 49.5 (± 20.7). A residual graft content of 4.3% (± 7.8) was observed following a healing time of 4.9 (± 0.8) months.

Conclusions: Clinical and histomorphometric data suggests that CPS putty is a good choice for socket bone regeneration

Compend Contin Educ Dent. 2012 Sep;33(8):e109-15.



Guided Bone Regeneration Simultaneously with

Alejandro Kovacs⁺ Georgios

⁺Resident, Advanced Education Program in Periodontology, University of Minnesota, MN, ++Pro

Implant Placement Utilizing an Alloplastic Putty

A Kotsakis⁺ Tarun Kumar ⁺⁺

Professor and Head, Department of Implantology, Bapuji Dental College & Hospital, Davangere, India

Sept 29 – Oct 1, 2013
Philadelphia, PA

Background

In edentulous sites where the residual ridge exhibits significant reduction in the orofacial plane that compromises the placement of an implant surrounded by adequate bone volume, ridge augmentation procedures should be employed. When guided bone regeneration (GBR) is performed simultaneously with implant placement to compensate for horizontal ridge deficiencies that leave implant threads exposed, it can significantly reduce healing time and eliminate the need for a second surgery, thus increasing patient acceptance. The aim of this case series is to report the clinical outcome of GBR with a calcium phosphosilicate (CPS) alloplastic putty bone substitute performed simultaneously with implant placement.

Methods

Twelve patients presenting with Class I Seibert defects in 14 edentulous sites were treated with GBR using a CPS putty with a collagen membrane (CM) or titanium mesh (TiM) following implant placement. In order to be included in the study, at least one implant thread had to be exposed on the facial aspect of the implant following implant placement. During 1st stage surgery, the distance from the most apical level of the bone crest on the facial aspect of the implant to the platform of the implant was estimated. The same measurement was retaken during second stage surgery. All patients were followed-up at least 6 months after delivery of the implant-supported restorations.

Representative Case 1

A 22 yr old male patient presented with an edentulous area in the lower left first molar area. The ridge width as measured at the crest was 3mm. A 4.2 mm x 11.5mm MIS Seven implant was placed in the area. A 4mm dehiscence defect was noted after implant placement. The area was decorticated to facilitate bleeding and a macroporous titanium mesh (0.1mm) was placed over the implant and contoured to adjacent bone envelope. The mesh was stabilized with titanium tacks. CPS Putty was injected inside the mesh through the sides using the unique cartridge delivery system. Tissues were approximated to get complete primary closure. There was no exposure of the titanium mesh during healing and second state re-entry was performed at 4.5 months for mesh removal.

Upon mesh removal, complete ridge regeneration in the area was noticed. The cover screw had to be exposed by scraping the newly formed bone using Piezo surgery. The implant was restored with PFM crown.

Representative Case 2

A 30 yr old female patient presented with edentulous area in the lower left first molar region. The buccolingual width was measured at 3mm at the crest of the ridge. A MIS Seven 4.2mm x 10mm implant was placed in the area. A dehiscence defect exposing approximately 4 mm of the implant was noticed. The area was decorticated to facilitate bleeding and a titanium mesh was placed and contoured to adjacent bone. The mesh was stabilized with titanium tacks and CPS putty was injected underneath the mesh through the sides and complete primary closure was achieved. Titanium mesh exposure was noticed 4 months post operatively and re-entry showed complete bone regeneration in the area. The cover screw was exposed by scraping the bone with Piezo instruments. The area was restored with PFM crowns.

Representative Case 1

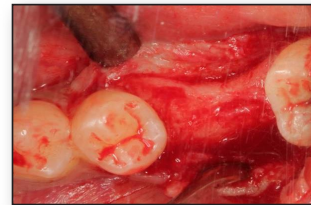


Fig 1: Surgical exposure of the site showing Buccolingual deficiency

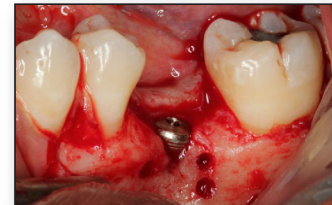

Fig 2: Implant placement with buccal dehiscence and decortication

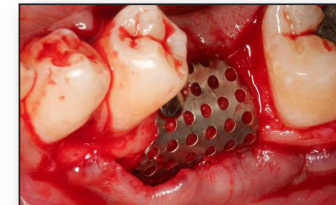


Fig 3: CPS putty grafted, covered with Titanium mesh and stabilized by titanium tacs

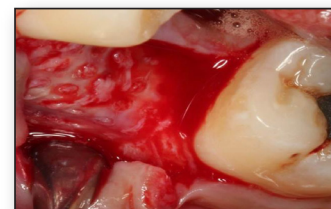

Fig 4: Second stage surgery after the removal of mesh showing complete bone formation over the dehiscence

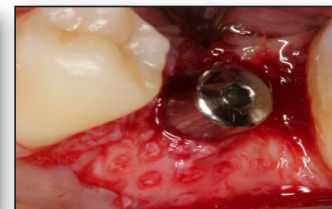


Fig 5: Note the complete reconstruction of the lost buccal contour

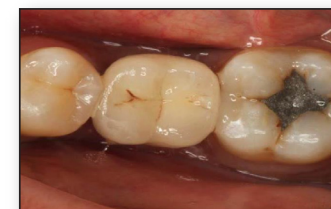

Fig 6: Final restoration in function

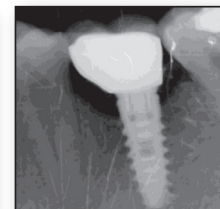


Fig 7: 18 months Post-Loading

Representative Case 2

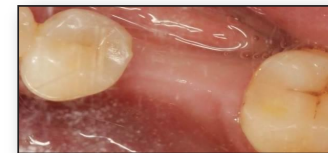

Fig 1: Pre operative view showing Buccolingual contour deficiency

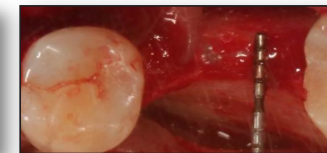


Fig 2: Surgical exposure of the site showing buccolingual ridge width of 3mm

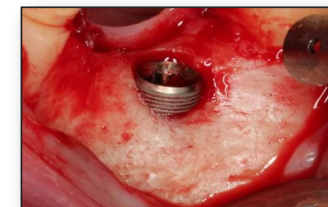


Fig 3: Implant placement with buccal dehiscence

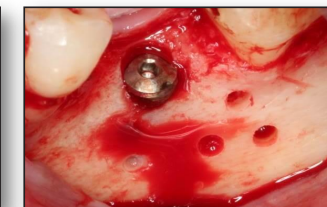

Fig 4: Decortication around the dehiscence defect

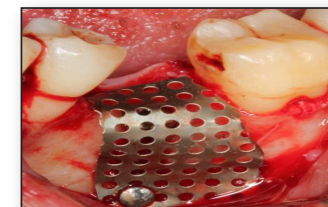


Fig 5: Mesh contouring to correct the Buccolingual ridge deficiency

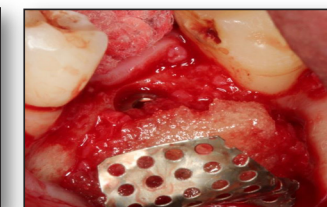


Fig 5: CPS putty utilized to graft the defect

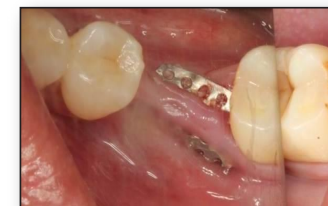

Fig 6: Titanium Mesh exposure at 4.5 months

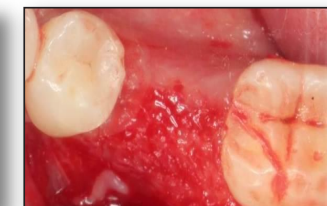

Fig 7: Second stage surgery after removal of mesh showing complete bone reformation

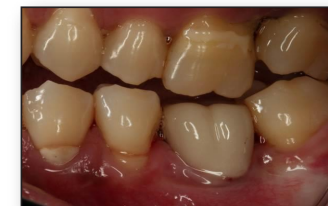

Fig 8: Final restoration

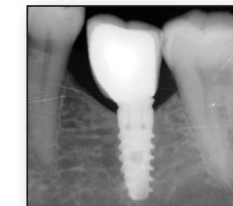


Fig 9: 14 months Post-loading

Results

In this study 6/14 sites were augmented with CPS putty and TiM while 8/14 were augmented with CPS putty and a CM. The average intra-operative defect measurement during 1st stage implant surgery was 4.57mm (±2.50). After a median healing time of 5 months (range: 4-7 months) patients were scheduled for 2nd stage surgery. Intra-operative measurements showed the average defect distance to be 0.14mm (±0.36), (P<0.01). Implants were not surrounded by hard tissue, resistant to probe penetration only in two sites that accounted for the above mentioned mean defect value measured at 2nd stage surgery. In one of the two cases with a remaining defect, a CM that was prematurely exposed had been used, while in the second case, a TiM had been utilized. In total, premature membrane exposure was noted in 2/6 cases with TiM and in 1/8 cases with CM. New tissue was almost completely covering the osseointegrated implant in the cases where premature TiM exposure occurred. All implants were successfully osseointegrated (14/14) at the time of 2nd stage and maintained successful osseointegration after a follow-up of at least 6 months post loading for a cumulative success rate of 100%.

Discussion

Guided Bone Regeneration is a very technique sensitive surgical procedure that requires the right combination of surgical techniques and biomaterial selection. Results from this 14 case series indicated that CPS Putty in combination with either a CM, or a Ti-mesh produced excellent bone regeneration in GBR surgeries.

CPS Putty is a third generation synthetic bone graft substitute. The material is cohesive and provides adequate retention at the defect site. Various studies indicate a capability possessed by CPS particles to stimulate differentiation towards cell lineage with therapeutic potential in tissue engineering.^{1,2} This unique phenomenon (osteo-stimulation) occurs exclusively with CPS based substitutes and has been shown to be superior to conventional osteoconduction. Recently several publications have been published on the bone regeneration efficacy of CPS Putty in a variety of indications.³⁻⁵

Conclusion

Calcium phosphosilicate putty can be a successful scaffold for new bone growth in GBR procedures. Both a collagen membrane and a titanium mesh can be employed in conjunction with CPS putty for bone regeneration around implants. TiM may exhibit a more frequent exposure rate, which was not found to compromise the clinical outcome in this study. Further randomized, controlled clinical trials are required to validate our results.

References

1. Carinci F, Palmieri A, Martinelli M, Perrotti V, Piattelli A, Brunelli G, et al. Genetic portrait of osteoblast-like cells cultured on bioactive glass. J Oral Implantol. 2007;33:327-33
2. Xynos ID, Edgar AJ, Buttery LDK, Hench LL, Polak JM. Gene-expression profiling of human osteoblasts following treatment with the ionic products of bioglass 45S5 dissolution. J Biomed Mater Res 2001;55(2):151-157
3. Mazor Z, Loannou A, Venkataraman N, Kotsakis G. Minimally invasive crestal approach technique for sinus elevation using a cartridge delivery system. Implant Practice 6(4):20-24
4. Kotsakis GA, Salama M, Chrepa V, Hinrichs J, and Gaillard P: A randomized, blinded, controlled clinical study of particulate Anorganic Bovine Bone Mineral and Calcium Phosphosilicate Putty bone substitutes for alveolar ridge preservation. In Press, September 2013. Int J Oral Maxillofac Implants
5. Mahesh L, Salama MA, Kurtzman GM, Joachim FP. Socket grafting with calcium phosphosilicate alloplast putty: a histomorphometric evaluation. Compend Contin Educ Dent. 2012 Sep;33(8):e109-15

Background

The alveolar bone deficiencies are caused due to various factors that include: trauma, faulty extraction, socket compression, and long term edentulism. At times, the quantity of the bone may be adequate for implant placement, but may not be in the proper location for an appropriate maxillo-mandibular relation and thus necessitate procedures to augment the ridge. Edentulous ridges can be split and expanded to widen a narrow ridge to accept a standard-sized implant. Alveolar ridge expansion with Piezo powered saw and subsequent expansion of the split bone with motorized expanders can create space for Immediate Implant Placement. The Piezoelectric Saw is ideal for performing precise bone cuts while offering better control on the expansion. The aim of this study was to place the implant immediately by ridge split using the Piezo unit and Calcium Phosphosilicate (CPS) for expanding the alveolar ridge.

Methods

A total of 15 patients who reported to the Department of Implantology and needed the correction of the deficient anterior maxilla were included in the study. All the patients were informed of the procedure and consent was taken. All the patients who were included in the study underwent a preoperative assessment that included models and wax-up to determine the desired tooth/implant positions. Afterwards, all the patients underwent a radiographic evaluation which included Periapical IOPAR and OPG. The following parameters were recorded during the study: 1. Pre-operative ridge width, 2. Post-operative ridge width during second stage while connecting healing caps, 3. Primary stability of the implants as measured in terms of insertion torque, 5. Implant survival and success.

Surgical Procedure

A Mid-crestal incision design was followed for all the cases with two vertical release incisions on the mesial and distal sides, and a full thickness flap was reflected. Using the piezo surgery, the sagittal bone cuts were made initially at the crest leaving at least 1 mm of margin at the palatal bone. The mesial and distal vertical cuts were made at a distance of 1 mm from the adjacent teeth. The implant sites were then designated as per the pre-operative plan with a pilot drill. Further expansion of the site was done with bone expanders (MIS expander screw kit) to the planned width. All the sites irrespective of implant placement were grafted with a calcium phosphosilicate alloplastic bone substitute, performed and covered with either collagen membrane or titanium mesh over the split, and the flaps were released to achieve primary closure.

Representative Case 1

A 45 year old female patient had lost her teeth due to trauma 4 months back and desired replacement of the missing teeth. Clinical examination revealed missing teeth no. 11, 12 and ridge deficiency on the buccal aspect. The ridge preoperatively at the crest was 2.5mm. CPS putty was injected between the split ridge. 4x13mm Neobiotec ISII implants were placed in the region of 11 and 12 utilizing the surgical stent. RCM collagen membrane was utilized to cover the grafted site. 4.5 months later, an impression was made and PFM cemented crowns were delivered to the patient.

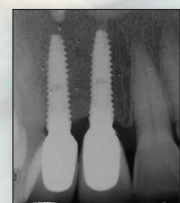
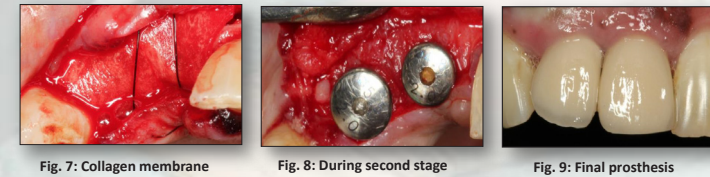
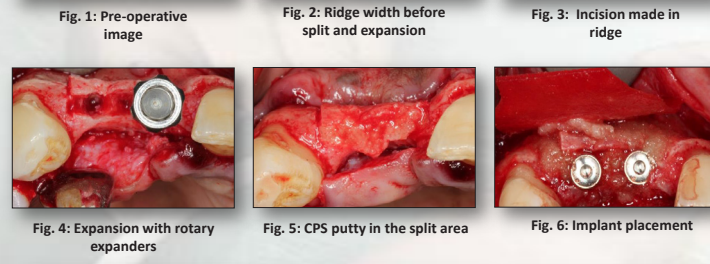
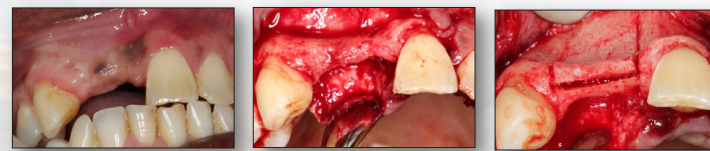

Fig. 10: 14 months post-loading showing crestal bone stability

Representative Case 1

Representative Case 2

A 32 year old male patient had many missing teeth due to periodontal disease which were extracted 2-4 years back. The patient desired replacement with implant-supported full arch restoration. Clinical examination revealed all the teeth were missing except canines and premolars. The anterior ridge in the region of the central incisor and lateral incisor was deficient on the buccal aspect. The radiographic findings and the implant planning revealed that the width was adequate and needed to be displaced buccal for optimal implant position. Pre-operative ridge width was 3mm. After splitting the ridge as per the protocol followed, CPS putty was injected between the split ridge. 3.8mmx12mm Biohorizons laserlok implants were placed in the region of 11 and 21 utilizing the surgical stent. RCM collagen membrane was utilized to cover the grafted site. 4.5 months later, an impression was made and hybrid screw retained was restoration delivered to the patient.

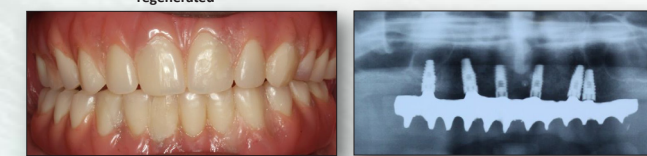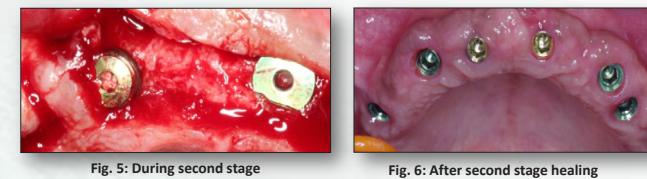
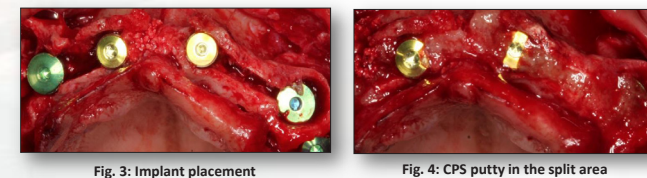
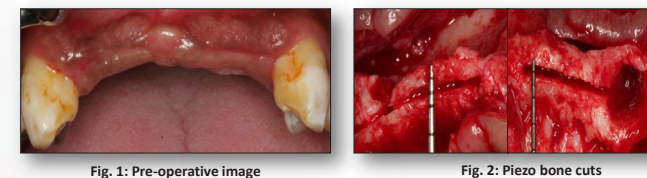


Fig. 7: Final restoration

Fig. 8: 12 months post-loading showing crestal bone stability

Representative Case 2

Results

The mean pre-operative ridge width was 2.9mm (range 2-4mm) and the post-operative width was 7.1mm (range 5.5-8mm). The smallest implant diameter was 3.5mm and the maximum was 4.6mm diameter (average of 3.8mm). The insertion torque was 25-35ncm (average of 24.6ncm) in the single-staged cases, whereas in the two-staged case, the torque at placement was 35-40ncm. 8 of the implants were restored with individual and remaining 22 with splinted crowns or bridge. None of the implants displayed any crestal bone loss, and the bone levels remained stable throughout the study.

Discussion

The alveolar ridge split procedure in combination with immediate implant placement has been described for more than 10 years. This procedure discards the need for onlay grafts. Moreover, it avoids the use of a secondary surgical site that exhibits postoperative morbidity associated with bone harvesting. In the present study we report a total of 15 cases where piezosurgical expansion of the maxillary anterior areas was done and 30 implants were placed. The total amount of expansion gained was 4.15mm which facilitated placement of implants. The grafting procedure was carried out to contour augment the buccal plate to give long-term stability to both hard and soft tissues and also to avoid accidental buccal bone resorption, which would happen when the split buccal bone is thin. There are several advantages of a one stage split and placement, including but not limited to reduction in overall treatment time by an approximate 12-14 weeks and better soft tissue control as the implant and the split heals at the same time. The soft tissue from the buccal side that gets displaced to close the split in the first surgery can be recovered, re-establishing an adequate zone of keratinised tissue on the buccal aspect.

Conclusion

It can be concluded that the piezoelectric alveolar ridge splitting technique is a very successful alternative for extended grafting procedures if the ridge shows adequate height. Implants can be placed simultaneously after the ridge split and expansion with adequate insertion torques and achieve 100% survival and success. There is enhanced ease of grafting using CPS putty in between split ridges before implant placements without any voids left behind. Significant ridge width enhancement can be achieved with the use of this technique. Bone regenerated with collagen membrane along with CPS putty graft is comparable to augmenting the site with bioactive glass graft and a titanium mesh. Simultaneous placement of the implant with the split reduced the total treatment time.

References

- Bassetti T, Bassetti M, Mericske-Stern T, Enkling N. "Piezoelectric alveolar ridge-splitting technique with simultaneous implant placement: a cohort study with 2-year radiographic results." *Int J Oral Maxillofac Implants.* 2013 Nov-Dec; 28(6):1570-80.
- Simon M, Baldoni M, Zaffe D. "Jawbone enlargement using immediate implant placement associated with a split-crest technique and guided tissue regeneration." *Int J Periodontics Restorative Dent.* Oct; 1(3-4): 116-23.
- Blus C, Szmukler-Moncler S. "Split-crest and immediate implant placement with ultra-sonic bone surgery: A 3-year life-table analysis with 230 treated sites." *Clin Oral Implants Res.* 2006; 17: 700-707.
- Coatnam GW, Mariotti A. "The segmental ridge-split procedure." *J Periodontol* 2003; 74: 757-770.
- Santaga M, Guariniello L, D'Andrea A, Tartaro G. "A modified crestal ridge expansion technique for immediate placement of implants: A report of three cases." *J Oral Implantol.* 2008; 34: 319-324.

Clinical results of implant placement in resorbed ridges using simultaneous guided bone regeneration: a multicenter case series.

Konstantinidis I, Kumar T, Kher U, Stanitsas PD, Hinrichs JE, Kotsakis GA.

Objectives: The purpose of this case series was to evaluate the new bone formation following guided bone regeneration (GBR) with a calcium phosphosilicate (CPS), alloplastic bone putty at peri-implant dehiscence defects and to assess survival rate of implants placed in the augmented sites after 12 months of function.

Methods: Implants were placed in patients exhibiting Seibert class I ridge defects resulting in peri-implant dehiscence defects. The defects were treated following GBR principles with the use of a CPS alloplastic bone graft putty in combination either with a collagen membrane or a titanium mesh. The height of each bony dehiscence was clinically measured at the time of implant placement and again during second-stage surgery. The percentage of complete defect coverage, frequency of adverse events, and risk factors for residual defect were determined.

Results: Thirty-six implants were placed in 26 patients. Twenty-seven of the 36 sites employed a collagen membrane in conjunction with the CPS while the remaining nine sites utilized a titanium membrane. Mean gain in bone height was 3.23 ± 2.04 mm, with 75 % of the peri-implant defects achieving complete regeneration. A negative correlation was identified between patient age and complete coverage of the peri-implant defect ($p=0.026$). The implant survival rate at 12 months was 97.22 %.

Conclusions: Use of CPS bone putty during delayed implant placement at peri-implant dehiscence sites either in combination with a collagen membrane or a titanium mesh results in predictable defect coverage. The handling characteristics of CPS putty may simplify GBR protocol. Implants placed in conjunction with GBR have a very good survival rate after 1 year of follow-up.

Clin Oral Investig. 2015 Mar;19(2):553-9.

Clinical and cone beam computed tomography comparison of NovaBone Dental Putty and PerioGlas in the treatment of mandibular Class II furcations.

Asmita, Gupta V, Bains VK, Singh GP, Jhingran R

Objective: The objective of this study is to compare the putty form of bioactive glass (NovaBone Dental Putty) and particulate form (PerioGlas) in the resolution of Class II furcation defects.

Background: Use of bone regeneration materials is becoming common in periodontal surgeries including furcation defects and the promising role of bioactive allograft materials has encouraged their presentation in different morphologic forms with their own advantages and disadvantages giving the operator ample of choices in his/her periodontal armamentarium.

Materials & Methods: A total of 28 patients with 40 Class II furcation defects were enrolled in the study and were randomly allocated to two groups with 20 sites in each group. Measurement of defects was done using clinical and cone beam computed tomography (CBCT) methods. The patients were followed-up at 6 months. Intergroup comparisons were done using Mann-Whitney U-test.

Results: There was no significance between group differences in clinical parameters and defect size at the baseline. After 6 months, particulate form showed a mean resolution of $50.48 \pm 16.47\%$ and $51.11 \pm 9.48\%$, respectively for vertical defect and horizontal defect while putty form showed a mean resolution of $43.48 \pm 9.33\%$ and $42.88 \pm 11.09\%$, respectively. Mean resolution in furcation width was $40.15 \pm 13.00\%$ for particulate form as compared with $36.27 \pm 11.41\%$ in putty form. Statistically, there was no significant difference between two groups except for the horizontal defect fill where PerioGlas showed statistically better results.

Conclusions: Putty form was comparable to particulate form for resolution of Class II furcation defects.

Indian J Dent Res. 2014 Mar-Apr;25(2):166-73.

Management of Fenestration Defects During Flapless Immediate Implant Placement in the Esthetic Zone.

Kher U, Tunkiwala A, Umriġar Z.

Abstract: The success of flapless immediate implant placement is dependent on the bony architecture on the buccal aspect of the socket. The presence of a fenestration defect in the buccal cortical plate may jeopardize the esthetic outcome, especially if the clinician does not undertake adequate soft and hard tissue augmentation procedures.

This article describes the use of an esthetic buccal flap design to deal with fenestration defects created during anterior implant placement immediately after extraction. This technique has been proven effective in maintaining the soft tissue architecture and allows hard tissue grafting of the fenestration defect around the implant in a postextraction socket.

Int J Periodontics Restorative Dent. 2015 Nov-Dec;35(6):e90-6.

IJPRD

Use of the NovaBone augmentation material in the treatment of chronic periodontitis. Preliminary communication.

Slezák R, Paulusová V.

Abstract: The pilot study deals with the clinical results of the regenerative therapeutical method in intraosseous periodontal defects done by surgical augmentation procedure using a material of a new generation prepared on the basis of a bioactive glass.

Methods: A group of 10 individuals were treated properly for chronic periodontitis. Some of treated infraalveolar periodontal lesions, both periodontal pockets and interradicular defects, persisted or recurred in posterior teeth. In order to eliminate them they were indicated for advanced periodontal surgery or regenerative surgical therapy stimulating healing processes of supportive tissues, mostly alveolar bone around treated teeth.

Results: Relevant clinical parameters, i. e. values of the pocket depth, gingival recession, and loss of attachment were evaluated before and after the periodontal surgery and compared with each other. The therapy led to significant improvement of clinical parameters in terms of the reduction of pocket depth and loss of attachment values.

Acta Medica (Hradec Kralove). 2013;56(4):157-61.

PUBLICATION LIST

Sinus Augmentation

1. A simplified approach to the minimally invasive antral membrane elevation technique utilizing a viscoelastic medium for hydraulic sinus floor elevation. Kotsakis GA, Mazor Z. Oral Maxillofac Surg. 2015; 19(1): 97-101.
2. A clinical and radiographic case series of implants placed with the simplified minimally invasive antral membrane elevation technique in the posterior maxilla. Kher U, Ioannou AL, Kumar T, Siompas K, Mitsias ME, Mazor Z, Kotsakis GA. J Craniomaxillofac Surg. Dec 2014; 42(8): 1942-7
3. One-stage transveolar vs. lateral maxillary sinus augmentation in severely resorbed sites using Calcium Phosphosilicate Putty: A proof of concept study. Kher U, Shanbhag S., Clin. Oral Impl. Res Oct 2014; 25(10).
4. Implants placed simultaneously with lateral-window sinus augmentation utilizing a calcium phosphosilicate putty alloplastic bone substitute for increased primary implant stability: A retrospective study. Udatta Kher, Ziv Mazor, Georgios A. Kotsakis, Panagiotis Stanitsas. Imp Dent 2014, 23(4):496-501
5. Sinus Elevation with an alloplastic material and simultaneous implant placement: A 1-stage procedure in severely atrophic maxillae. Jodia K, Sadhwani B, Parmar BS, Anchlia S, Sadhwani SB., J Maxillofac. Oral Surg (July-Sept 2014) 13(3):271-280
6. Minimally Invasive Crestal Approach Technique Utilizing a Cartridge Delivery System. Mazor Z, Ioannou A, Venkataraman N, Kotsakis G, Kher U., Implant Practice. Sept 2013; 6(4): 20-24.
7. Clinical and histologic comparison of two different composite grafts for sinus augmentation: a pilot clinical trial. Galindo-Moreno P, Avila G, Wang HL, et al., Clin Oral Implants Res. Aug 2008; 19(8): 755-9.

Socket Preservation

1. Clinical Evaluation of 262 Osseointegrated Implants Placed in Sites grafted with Calcium Phosphosilicate Putty: A Retrospective Study. Babbush CA, Kanawati A., J Oral Implantol. Feb 2015; 41(1): 62-9.
2. One-stage transveolar vs. lateral maxillary sinus augmentation in severely resorbed sites using Calcium Phosphosilicate Putty: A proof of concept study. Kher U, Shanbhag S., Clin. Oral Impl. Res Oct 2014; 25(10).
3. Periosteal Values of Implants Placed in Sockets Augmented with Calcium Phosphosilicate Putty Graft: A Comparative Analysis against Implants Placed in Naturally Healed Sockets. Mahesh L, Narayan T, Kostakis G, Shukla S. J Contemp Dent Pract. 2014 Mar 1;15(2):181-5.
4. Ridge Preservation with Socket Plug Technique Utilizing an Alloplastic Putty Bone Substitute or a Particulate Xenograft. Mahesh L, Kotsakis G, Venkataraman N, Shukla S, Prasad H., J Oral Implantol. Apr 2015; 41(2): 178-83.
5. A Randomized Blinded Controlled Clinical Study of Particulate Anorganic Bovine Bone Mineral and Calcium Phosphosilicate Putty Bone Substitutes for Socket Preservation. Kotsakis G, Salama M, Chrepa V, Hinrichs JE, Gaillard P., Int. J Oral Maxillofacial Implants. Jan-Feb 2014; 29(1):141-51
6. Histomorphologic Evaluation of a Calcium-Phosphosilicate Putty Bone Substitute in Extraction Sockets. Kotsakis G, Joachim F, Saroff S, Mahesh L, Prasad H, Rohrer M. Int J Periodontics Restorative Dent. 2014 Mar-Apr; 34(2):233-9.
7. Histologic and Clinical Evaluation of a Bioactive Calcium-Phosphosilicate Bone Graft Material in Post-Extraction Alveolar Sockets. Gonshor A, Lanka M, Saroff S et al., JIACD Dec 2011; 3(7): 21- 31.
8. Socket grafting with calcium phosphosilicate alloplast putty: A histomorphometric evaluation. Salama MA, Lanka M, Kurtzman GM, Joachim FPC, Compend Contin Educ Dent. Sept 2012; 33(8): 109-115.
9. Practical application of the newly introduced natural bone regeneration (NBR) concept utilizing alloplastic putty. Kotsakis G, Chrepa V, Katta S Int. J Oral Imp Clin Res Sept-Dec 2011; 2(3):145-149.
10. Ridge preservation with a calcium phosphosilicate putty in 12 consecutive cases.. Kotsakis G, Chrepa V, Katta S., Clin Oral Implants Res. Sept 2011; 22(9):10-24.

GBR / Ridge Augmentation

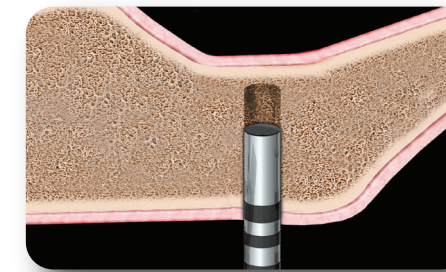
1. Management of fenestration defects during flapless immediate implant placement in esthetic zone. Kher U, Tunkiwal A, Umrigar Z., Int J Periodontics Restorative Dent. Nov-Dec 2015; 35(6):e90-6
2. Guided bone regeneration using titanium mesh with calcium phosphosilicate alloplast in the esthetic zone: A case report. Lanka M, Lahori M, Nagrath R, Sudan R., Int J Ultrasound Piezoelect Bone Surg June 2014; 3(1): 19-24
3. Clinical results of implant placement in resorbed ridges using simultaneous guided bone regeneration: a multicenter case series. Konstantinidis I, Kumar T, Kher U, Stanitsas PD, Hinrichs JE, Kotsakis GA., Clin Oral Investig. 2015 Mar;19(2):553-9.
4. Removal of a large radicular cyst and simultaneous ridge regeneration utilizing alloplastic CPS putty in combination with platelet rich fibrin (PRF): A case report. Kotsakis G, Chrepa V., JIACD Apr 2012; 4(2): 41-47.
5. Extraction of an impacted maxillary canine with immediate implant placement. Salama M, Lanka M, Kurtzman G., Inside Dentistry Mar 2012: 64-67.

Perio Defects

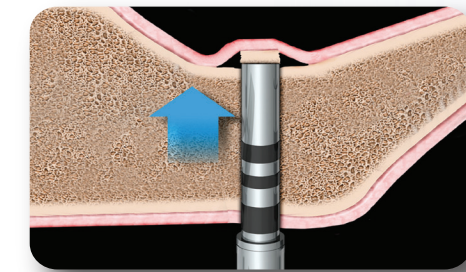
1. Clinical and cone beam computed tomography comparison of NovaBone Dental Putty and PerioGlas in the treatment of mandibular class II furcations. Asmita, Gupta V, Bains VK, Singh GP, Jhingran R., Indian J Dent Res, 2014 25(2):166-73
2. Use of the NovaBone augmentation material in the treatment of chronic periodontitis. Preliminary communication. Slezak R, Paulusova V., ACTA MEDICA (Hradec Kralove) 2013;56(4):157-161
3. Evaluation of the efficacy of bioactive synthetic graft material in the treatment of intrabony periodontal defects. Grover V, Kapoor A, Malhotra R, Uppal RS, J Indian Soc Periodontol. Jan-Feb 2013; 17(1): 104-110.

Minimally Invasive Transcrestal Sinus Augmentation

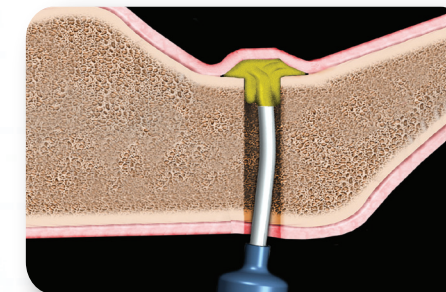
There are several ways to access the sinus via crestal approach and elevate the sinus membrane prior to augmentation: A) Osteotome technique B) Piezo Technique C) Neurosurgical Bur D) Densah Burs, etc. Bone graft delivery into the sinus can be difficult and challenging. NovaBone Cartridge System simplifies the delivery of graft into the sinus when accessed through the crest of the ridge. The tip of the cartridge is 2.8 mm in diameter and was designed specifically to deliver the graft seamlessly into the sinus. Putty consistency can help prevent membrane tears. The delivery of the putty graft can elevate the membrane with minimal instrumentation and hydraulic pressure.



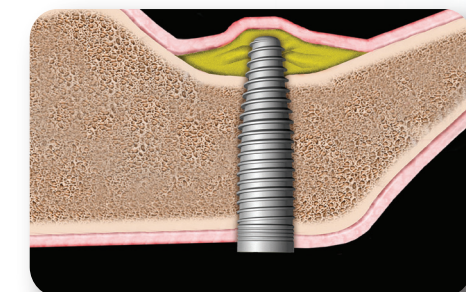
Step 1



Step 2



Step 3



Step 4

Easy access into sinus through crestal floor for sinus augmentation with Osteotome technique can be achieved in 4 simple steps. **Step 1:** Prepare the osteotomy to less than 1mm from the sinus floor. **Step 2:** An osteotome is then used to gently fracture the bone in the area. **Step 3:** The canula from the cartridge tip can be pressed against the surface of the bone and the putty is injected into the area resulting in membrane elevation with hydraulic pressure from Putty delivery. **Step 4:** An implant can then be placed in the augmented area.

Testimonials:

"The unique handling characteristics of the NovaBone putty in combination with the cartridge delivery system allow for significant simplification of routinely used techniques in implant dentistry and significant reduction in intra-operative treatment time" Dr. George Kotsakis, Periodontist, Assistant Prof., Univ. Washington, Seattle.

"The putty consistency of NovaBone is easy to manipulate, and the unique cartridge delivery allows access to unreachable areas. I am able to do sinus grafts through smaller windows with reduced intra-operative complications. The radiopacity of the material is optimum for visibility on a radiograph. Above all, the material holds its form long enough to facilitate new bone formation" Dr. Udatta Kher, Oral Surgeon, Private Practice, Mumbai, India

NOVABONE[®]
DRIVING INNOVATION IN OSTEOBIOLOGICS

Signal genetic pathways to build strong bone fast!

NovaBone Dental Putty redefines
minimally invasive bone grafting surgeries!

No Mixing ♦ Easy Handling ♦ Exceptional Results

NovaBone Dental Putty will truly revolutionize the way you use bone graft substitutes. You won't believe how easy the putty handles, yet delivering outstanding outcomes you demand.

Experience the sheer simplicity of NovaBone Dental Putty!

Think Productivity ♦ Think Putty

NOVABONE[®]
DRIVING INNOVATION IN OSTEOBIOLOGICS

NORTH AMERICA


NovaBone Products, LLC
13510 NW US Hwy. 441
Alachua, FL 32615
Ph: +1 (855) - 265 - 8013
www.novabone.com

INDIA

NovaBone Products Pvt. Ltd.
Suite 203, Excellency Bldg.
8 Papanna Street, St. Marks Road
Bangalore 560001
Ph: +91 80 4095-8299
www.novabone.in

CHINA

NovaBone China
Central Plaza 10th Floor #1037
Shanghai 200020
Ph: +86 21 6391-5870
www.novabone.com.cn

 www.facebook.com/nbputty

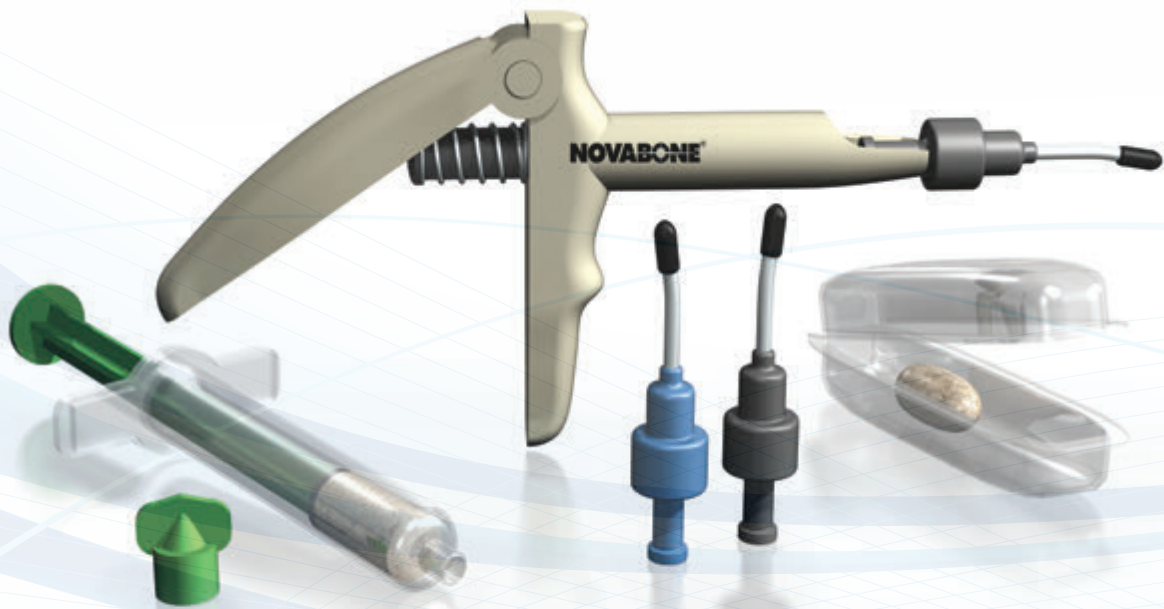0D8380-6

NOVABONE[®] Dental Putty

Product Guide

The Synthetic Solution to Bone Regeneration

Uncommon Handling... ...Uncompromised Results!



NovaBone Putty is available in multiple dispensing systems. Variations are priced for affordability and efficiency. Products are available through a network of distributors world-wide, with a presence in over 40 countries.

CARTRIDGE SYSTEM

Cartridge Dispenser	each
0.5cc Cartridges (blue)	2/Pack
0.5cc Cartridges (blue)	4/Pack
0.25cc Cartridges (grey)	4/Pack

SYRINGE

0.5cc Syringe	1/Pack
0.5cc Syringe	2/Pack
1.0cc Syringe	1/Pack
2.0cc Syringe	1/Pack

CLAM SHELL

0.5cc Shell	1/Pack
0.5cc Shell	2/Pack

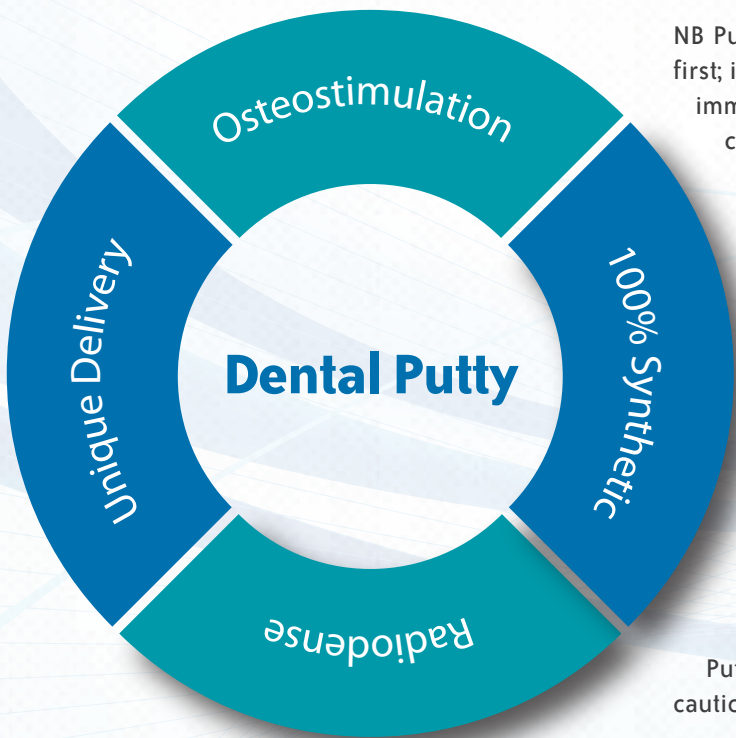
NovaBone Dental Putty

*The next generation Calcium-Phosphosilicate
bone substitute engineered for enhanced handling and
improved performance*

Product Characteristics

NovaBone Dental Putty was introduced after extensive market research which suggested that clinicians did not expect great strides in the rate of bone formation but rather in delivery, handling and performance of bone graft substitutes without a significant cost increase.

NB Putty has bimodal particle distribution of Calcium Phosphosilicate (CPS) (active ingredient), with Polyethylene Glycol (PEG) as an additive and Glycerin as the Binder. The volume of the active ingredient is approximately 70%. The Putty format allows easier manipulation due to its format and eliminates the need for any preparation prior to placement. NB Putty offers clinicians various delivery systems (Shells, Cartridges & Syringes) in various sizes with benefits of consistent, reliable bone regeneration. Putty received its FDA & CE approval for dental indications in 2006-07.



NB Putty is available in unique uni-dose cartridges – an industry first; ideal for minimally invasive surgeries, hard to access defects, immediate implant surgeries, osteotome sinus surgeries, etc. Each cartridge holds 0.25-0.5cc of putty.

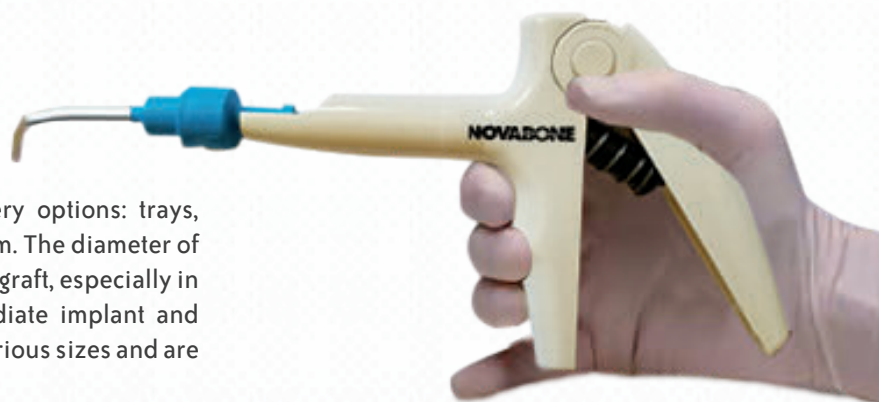Putty does not set like a cement. CPS has a transient hemostatic effect providing a comfortable environment for the clinician to work with. It encourages clot stabilization and promotes healing. Putty has good retention and can adapt to the defect shape.

Putty is **radio-dense** and can be visualized on radiographs. Upon implantation, it appears as a mass at the defect site which can be differentiated from surrounding bone by the lack of trabecular pattern. Over time, with bone remodeling, the grafted area appears analogous to the natural bone in the region.

Putty has a **4 year shelf life** does not need refrigeration but caution should be exercised at temperatures higher than **45 C**.

Superior Delivery System

NovaBone Dental Putty is available in multiple delivery options: trays, pre-filled syringes and a unique cartridge delivery system. The diameter of the cannula is 2.8mm which is ideal for dispensing of the graft, especially in minimally invasive techniques such as gaps in immediate implant and crestal approach sinus lifts. Cartridges are available in various sizes and are used in conjunction with cartridge dispenser.



Smart Science™ - Osteostimulation

Unlike other synthetic grafts that are bioinert, NB Putty belongs to the class of bioactive regenerative materials that not only acts as an osteoconductive scaffold but also interacts with the surrounding tissues and imparts an osteostimulatory effect. NB Putty is not osteoinductive but a number of in vivo studies have demonstrated an accelerated bone formation with CPS particles. Also, the viability and proliferation potential of osteoblasts has been shown to be accelerated in the presence of CPS particles. Studies also demonstrate increased osteocalcin and alkaline phosphatase levels in the presence of CPS particles providing a favorable environment for bone formation.

Osteostimulation is an active process. NovaBone Dental Putty acts as a bone matrix and encourages differentiation of new bone cells at the site. This phenomenon results in faster bone regeneration than exhibited by osteoconduction alone while simultaneously increasing the resorption rate of the graft material.

Biologic Interpretation

- § Immediately upon implantation, silicon and calcium ion release initiates a cascade of events that signals and recruits undifferentiated cells to the site
- § Several genes are regulated, resulting in proliferation and differentiation of undifferentiated cells into osteoblasts
- § The osteoblasts mature into osteocytes (mature bone cells) at the terminal stage
- § This process continues resulting in bone regeneration at a much faster pace than osteoconduction

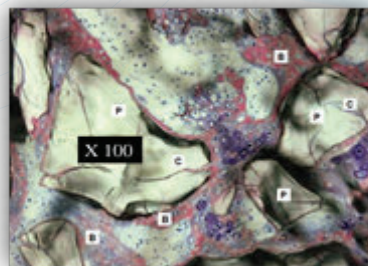
Clinical Interpretation

- § Upon implantation, the binder gets absorbed within 24-72 hrs, creating a 3-dimensional porous scaffold that facilitates active movement of blood and tissue fluids through the matrix
- § Smaller CPS particles interact with blood providing the initial burst of calcium and phosphate ions
- § This provides a favorable area for bone regeneration as it creates numerous calcium phosphate nodules that mature individually to form bone throughout the defect
- § Subsequently, the larger particles react and continue the process of bone regeneration

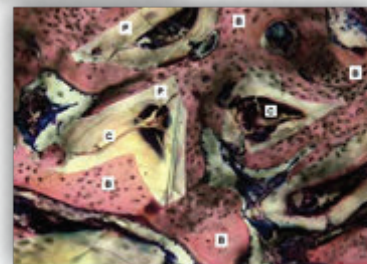
Histologic Interpretation

Rabbit Histology at 3 and 6 weeks helps visualize the osteostimulation phenomenon. At 3 weeks, cracks developing through individual particles can be noticed with bone growing through them. Pink areas of bone formation are also seen around the putty particles along with areas of cartilaginous cells & giant cells (purple).

At 6 weeks, abundant bone around each particle can be seen (pink areas). The cracks have progressed completely into the center of each particle, and an area of bone regeneration (pink) is seen within each individual particle. This is very unique to CPS products and results in the creation of multiple foci of bone regeneration resulting in enhanced bone regeneration and consequently faster material absorption!



3 Weeks



6 Weeks

B- Bone, P- Graft Particle, C- Cracks

Clinical Evidence

With over 50 technical publications and 32 clinical publications in peer reviewed journals, NB Putty has consistently proven to regenerate bone in various osseous defects including ridge augmentations, sinuses, sockets, periodontal defects, etc. Most studies suggest approx. 80%-90% graft absorption in 4-6 months, while regenerating bone at the same time.

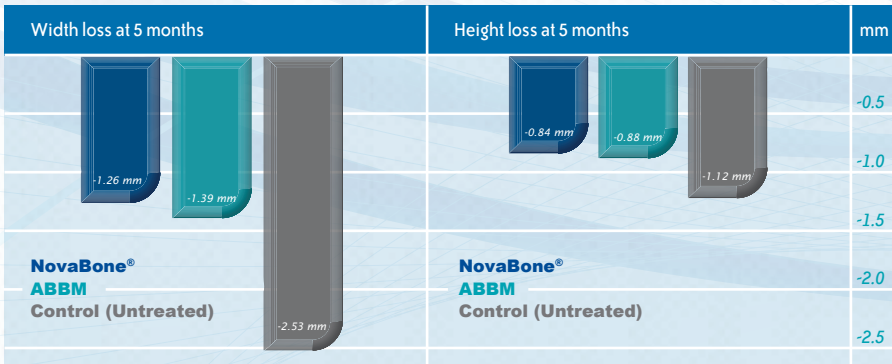
NB Putty with its unique cartridge delivery system has redefined sinus augmentation surgeries facilitating minimally invasive surgical approaches and improvisations. NB Putty with its handling characteristics acts as an excellent carrier for guided bone regeneration surgeries in combination with NovaBone Morsels or Allograft bone (1:1).



Comparison with Bovine Bone

2015 JOI article by Lanka et al., evaluated both NB Putty & Bovine xenograft histomorphometrically. They concluded that ridge preservation using a putty calcium phosphosilicate alloplastic bone substitute results in more timely graft substitution and increased bone regeneration when compared to an anorganic bovine bone xenograft.

In a 2014 JOMI article, Kotsakis et al., published data from a blinded randomized controlled trial comparing dimensional changes at 5 months following socket preservation using NovaBone Dental Putty (PUT) or anorganic bovine bone mineral (ABBM), both groups showed a statistically significant reduction in ridge width loss.



NovaBone® treated sites showed comparable results to sites treated with ABBM in both width and height changes. The maximum implant insertion torque (MIT) was measured as an index of primary implant stability. MIT for PUT was ≤ 35 N/cm² (MIT grade 4) for seven of the nine implants. MIT values in the ABBM group ranged from grade 1 (10 to 19 N/cm²) to grade 4, which was statistically significantly lower than the

PUT group. The overall implant success rate was 94.1% (16 of 17 implants were successful). They concluded that Putty was good to preserve ridge dimensions and had favorable bone density values for implant placement.

Histomorphometry

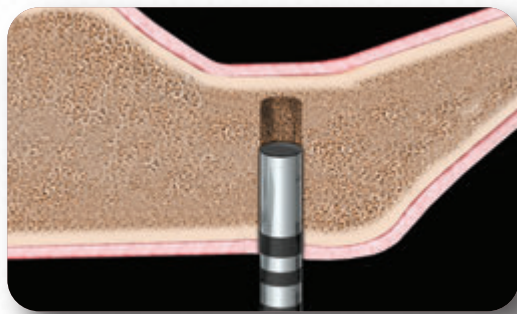
In four separate studies, histomorphometric evaluation of cores taken from extraction sockets grafted with NovaBone Dental Putty showed vital bone regeneration and significant graft resorption.^{1,2,3,4}

	Number of Sites	Average Re-Entry Time	Mean Vital Bone Content	Mean Residual Graft
2015 Lanka et al. ¹	N = 10	4.9 months	47.15%	17.4%
2014 Kotsakis et al. ²	N = 17	5.7 months	31.76%	11.47%
2012 Lanka et al. ³	N = 20	4.9 months	49.57%	4.3%
2011 Gonshor et al. ⁴	N = 22	5.4 months	48.2%	2.4%

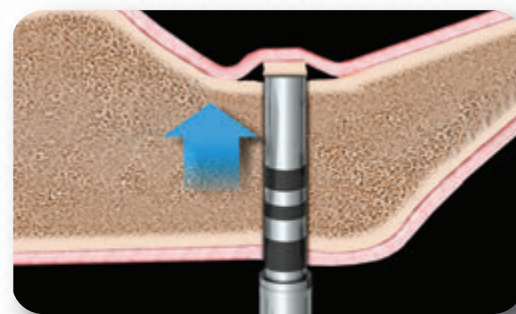
1. Lanka M, et al. Alveolar ridge preservation with the socket-plug technique utilizing an alloplastic putty bone substitute or a particulate xenograft: a histological pilot study. J Oral Implantol 2015 Apr; 41(2):178-83
 2. Kotsakis GA, et al. Histomorphometric evaluation of a calcium-phosphosilicate putty bone substitute in extraction sockets. Int. J Periodontics Restorative Dent. 2014 Mar-Apr; 34(2):233-9
 3. Lanka M, et al. Socket grafting with calcium phosphosilicate alloplast putty: a histomorphometric evaluation. Compend Contin Educ Dent. 2012 Sep;33(8):e109-15.
 4. Gonshor A, et al. Histologic and Clinical Evaluation of a Bioactive Calcium Phosphosilicate Bone Graft Material in Postextraction Alveolar Sockets. Int J Oral Imp and Clin Res. 2011;2(2): 79-84.

Minimally Invasive Transcrestal Sinus Augmentation

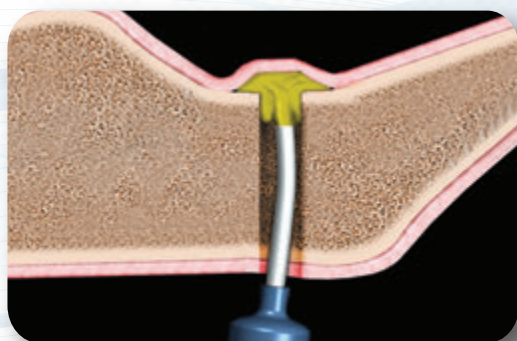
There are several ways to access the sinus via crestal approach and elevate the sinus membrane prior to augmentation: A) Osteotome technique B) Piezo Technique C) Neurosurgical Bur D) Densah Burs, etc. Bone graft delivery into the sinus can be difficult and challenging. NovaBone Cartridge System simplifies the delivery of graft into the sinus especially when accessed through the crest of the ridge. The tip of the cartridge is 2.8 mm in diameter and was designed specifically to deliver the graft seamlessly into the sinus. Putty consistency can help prevent membrane tears. The delivery of the putty graft can elevate the membrane with minimal instrumentation and hydraulic pressure.



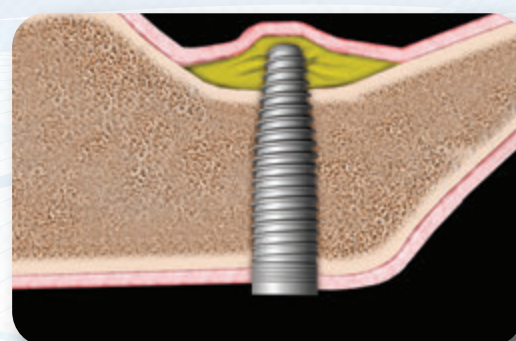
Step 1



Step 2



Step 3



Step 4

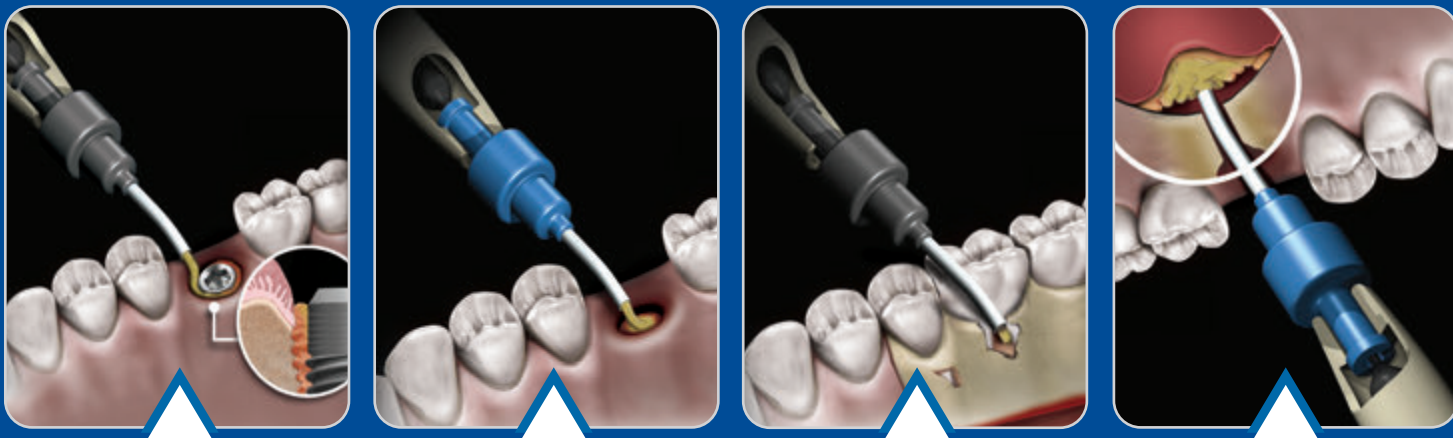Easy access into sinus through crestal floor for sinus augmentation with Osteotome technique can be achieved in 4 simple steps. **Step 1:** Prepare the osteotomy to less than 1mm from the sinus floor. **Step 2:** An osteotome is then used to gently fracture the bone in the area. **Step 3:** The canula from the cartridge tip can be pressed against the surface of the bone and the putty is injected into the area resulting in membrane elevation with hydraulic pressure from Putty delivery. **Step 4:** An implant can then be placed in the augmented area.

Testimonials

“The unique handling characteristics of the NovaBone putty in combination with the cartridge delivery system allow for significant simplification of routinely used techniques in implant dentistry and significant reduction in intra-operative treatment time” Dr. George Kotsakis, Periodontist, Assistant Prof., Univ. Washington, Seattle.

“The putty consistency of NovaBone is easy to manipulate, and the unique cartridge delivery allows access to unreachable areas. I am able to do sinus grafts through smaller windows with reduced intra-operative complications. The radiopacity of the material is optimum for visibility on a radiograph. Above all, the material holds its form long enough to facilitate new bone formation” Dr. Udatta Kher, Oral Surgeon, Private Practice, Mumbai, India

GRAFTING SIMPLIFIED



Dental Putty cartridge system redefines
minimally invasive bone grafting surgeries!

No Mixing • **Easy Handling** • **Exceptional Results**

NovaBone Dental Putty will truly revolutionize the way you use bone graft substitutes. You won't believe how easy the putty handles, yet delivering outstanding outcomes you demand.

Experience the sheer simplicity of NovaBone Dental Putty!

Think Productivity • Think Putty

NOVABONE®

DRIVING INNOVATION IN OSTEOBIOLOGICS

NORTH AMERICA

NovaBone Products, LLC
13510 NW US Hwy. 441
Alachua, FL 32615
Ph: +1 (855) - 265 - 8013
www.novabone.com

INDIA

NovaBone Products Pvt. Ltd.
Suite 203, Excellency Bldg.
8 Papanna Street, St. Marks Road
Bangalore 560001
Ph: +91 80 4095-8299
www.novabone.in

CHINA

NovaBone China
Central Plaza 10th Floor #1037
Shanghai 200020
Ph: +86 21 6391-5870
www.novabone.com.cn